

## Research article

**Assessment of the vertical relationship between the maxillary posterior teeth and the maxillary antral floor in a South Indian population using Cone Beam Computed Tomography- A radiographic observational study**K.V.Swathi<sup>1</sup>, G. Maragathavalli<sup>2</sup><sup>1</sup>Department of Oral Medicine and Radiology, SRM Dental College, Ramapuram, Chennai, 600089, Tamil Nadu, India<sup>2</sup>Department of Oral Medicine and Radiology, Saveetha Dental College, Chennai, 600077, Tamil Nadu, India

(Received: January 2022

Revised: May 2022

Accepted: June 2022)

Corresponding author: K.V.Swathi. Email:1993kvs@gmail.com

**ABSTRACT**

**Introduction and Aim:** Maxillary sinus, also known as the Antrum of Highmore, is said to be one of the largest pyramidal shaped paranasal sinuses that begins at the 10<sup>th</sup> week of intrauterine development and undergoes pneumatization. The root apices of the maxillary posterior teeth have a proximity to the antral floor, so a thorough understanding of this anatomical relationship is very essential as it can have an important influence during dental procedures such as implant planning, extractions, and certain other oral and maxillofacial surgeries. The aim of this study was to assess the vertical relationship between the posterior teeth in the maxillary arch with the floor of the maxillary antrum, using Cone Beam Computed Tomography (CBCT) in a South Indian population.

**Materials and Methods:** This was a retrospective analysis of 50 right or left maxillary sinuses in panorama and tangential sections by tracing the outline forms of the maxillary antral floor and also measuring its vertical distance from maxillary posterior root apices.

**Results:** Four types of relationship patterns were observed between the maxillary antral floor and root apices of the maxillary posteriors. The root apices of the maxillary second molar were found to be in close proximity with the maxillary sinus (2.27mm) and similar observation was found in the left side with the left second molar to be in close proximity to the sinus (2.04 mm).

**Conclusion:** The assessment of this vertical relationship is very important during extractions, implant planning or during any other surgeries in the maxillofacial region.

**Keywords:** Maxilla; posterior teeth; maxillary sinus; antral floor; Cone Beam Computed Tomography

**INTRODUCTION**

There are four pairs of paranasal sinuses in humans that include frontal, sphenoid, ethmoid and maxillary sinuses of which the maxillary sinus, known as Antrum of Highmore which is one of the largest pyramidal shaped paranasal sinus that begins to form during the 10<sup>th</sup> week of intrauterine development. The mucosa that is located at the deeper anterior end of the ethmoid infundibulum has invaginations toward the surrounding mesenchyme and it fuses during the 11<sup>th</sup> week of intrauterine development which results in the formation of the primordial cavity of the maxillary sinus that is seen as an oval cavity with smooth walls (1). The maxillary sinus drains into the middle meatus through the osteomeatal complex. The antrum has three recesses: Inferiorly, it has an alveolar recess bounded by the alveolar process of the maxilla; laterally has a zygomatic recess bounded by the zygomatic bone; and superiorly an infraorbital recess bounded by the inferior orbital surface of the maxilla (2). The antrum as such is bounded superiorly by the uncinate process of the ethmoid, inferiorly by the ethmoidal process of the inferior nasal concha, anteriorly by a small portion of the lacrimal above and

the posteriorly by the vertical portion of the palatine bone. The anatomy of maxillary antrum is said to vary among each individual and it undergoes a physiological process with age known as pneumatization which is characterised by the formation of air cells within the antrum which causes the sinus to expand in its volume. This pneumatization process is governed by previous infections, certain genetic diseases and other environmental conditions (3).

The pathologies of the maxillary antrum include intrinsic diseases which primarily originate from the walls of the antrum and extrinsic diseases that develop outside the sinus that may cause an infiltration or impingement into the sinus like mucosal thickening, polypoidal soft tissue growths, partial opacification with mucous accumulation, complete opacification, mucous retention cysts, retained root stumps, impacted teeth, antroliths, exostosis, oro-antral fistulas or communications and certain other benign or malignant lesions (4).

The maxillary antrum expands between the root apices of the maxillary molars which results in its close

proximity of its floor with the posterior teeth in the maxillary arch. There are certain clinical implications due to this close proximity. Extractions, endodontic surgery can increase the risk of antral perforation or formation of oro-antral fistula. There are also chances of displacement of the root tips if there is close approximation of the maxillary root apices with the maxillary antrum (5). This vertical relationship should also be considered during orthodontic tooth movements.

Conventional radiographs like intraoral periapical and orthopantomogram can offer some information on this vertical relationship. Cone Beam Computed Tomography (CBCT) provides greater detailing, finer resolution and aids in the measurements of the apical portion of the root tip from the floor of the maxillary antrum to evaluate this vertical relationship (6). The relationship of the maxillary antrum with the maxillary posterior teeth can be of different types. The root apices of the maxillary posterior teeth can be below or outside the antral floor; it may be contacting the floor or may be above or inside the floor of the antrum (7).

Literature also throws light on other classification systems defining this vertical relationship. According to Kwak *et al.* there are 5 types of relationship between the maxillary posterior root apices and the maxillary antral floor. The first is Type I relationship which is seen as the inferior wall of the maxillary sinus floor is located above the root apex of the buccal and palatal roots, type II relationship is seen when the inferior wall of the antrum is located below the level that connects the buccal and palatal root apices without an apical protrusion over the antrum. In type III, apical protrusion of the buccal root apex is seen over the inferior wall of the antrum, in type IV relationship there is an apical protrusion of the palatal root apex observed over the inferior wall of the antrum and in type V relationship apical protrusions of both the buccal and palatal root apices are observed over the inferior wall of the antrum. For single rooted teeth, the classification of the vertical relationship is as follows; Type I where the inferior wall of the antrum is located above the root apex, in type II, the root apex touches the inferior wall of the antrum and type III, apical protrusion of the root apex is observed over the inferior wall of the maxillary sinus (8).

Studies have also found that the maxillary second molars have a close proximity to the maxillary sinus floor of which the palatal root tip has a closer proximity to the maxillary antral floor (9). Pneumatisation of the maxillary sinus can be affected by various factors such as heredity, post sinus surgery, effect of growth hormones and air pressure of the

sinus (10). The loss of teeth in the maxillary posterior region may induce pneumatisation of the sinus leading to union between the sinus floor and the alveolar crest in certain scenarios as reported in the literature (11).

## MATERIALS AND METHODS

A random retrospective analysis of 50 maxillary Cone Beam Computed Tomography (CBCT) scans (Images taken using Sirona Orthophos XG 3D CBCT scanner 8 x 8 Field of view) were analysed using Galileos implant viewer software. The maxillary sinuses were analysed in panorama and tangential sections.

The outline of the floor of the maxillary sinus was traced in all the images. The vertical measurement was done by measuring the distance of the root apices of maxillary first premolar, second premolar, first molar and second molar to the floor of the maxillary sinus. It was measured by connecting a line from the central point of the apex of both the single and multi-rooted teeth with the floor of the maxillary antrum. (Fig. 3)

## RESULTS

Four types of pattern of the maxillary antral floor with the maxillary posterior teeth root apices were observed. (Fig. 1)

Type 0: There was no contact of the maxillary posterior teeth with the floor of the maxillary antrum.

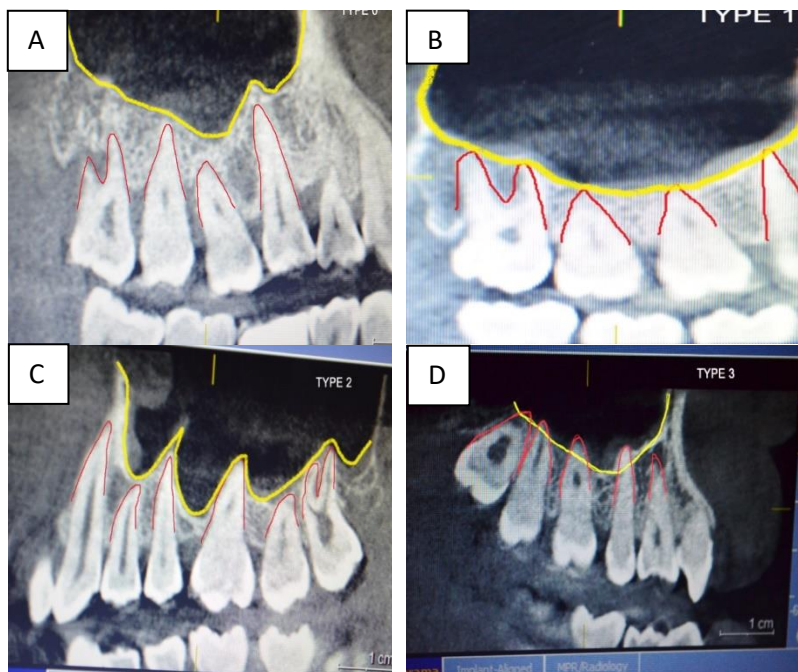
Type 1: The maxillary antral floor touches the root apices of the maxillary posterior teeth.

Type 2: The maxillary antral floor is seen to protrude between the roots of the maxillary posterior teeth.

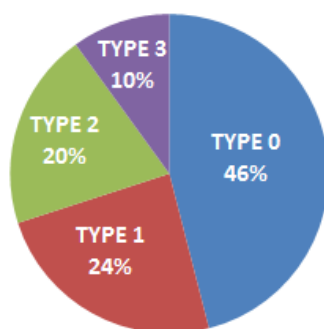
Type 3: The maxillary antral floor is seen to project uniformly across the roots of the maxillary posterior teeth.

Type 0 was the most common (46 %), followed by Type 1 (24%), Type 2 (20%) and Type 3 (10%) (Fig. 2)

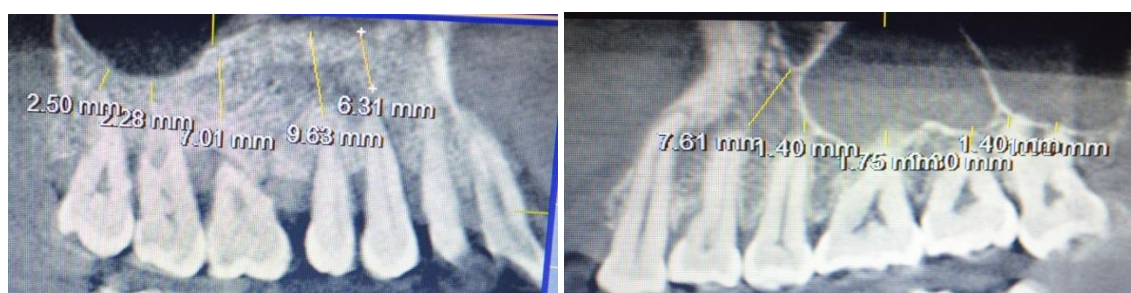The average distances of right, left maxillary posterior teeth from maxillary first premolar, second premolar, first molar and second molar with floor of the maxillary sinus has been tabulated. (Tables 1 and 2). The root apices of the maxillary right second molar was found to be in close proximity with maxillary sinus floor (2.27mm) and similarly in the left quadrant, the root apices of the maxillary left second molar was found to be in close proximity with the maxillary sinus floor (2.04 mm).



**Fig. 1:** Different type of maxillary antral floor patterns with the maxillary posterior teeth  
A) Type 0 B) Type 1 C) Type 2 D) Type 3



**Fig. 2:** Distribution of the vertical relationship patterns of the maxillary posterior teeth with the maxillary sinus floor



**Fig. 3:** Vertical measurements of the apices of maxillary posterior teeth (maxillary first premolar, second premolar, first molar and second molar) with floor of the maxillary sinus

**Table 1:** Average distances of the root apices of the maxillary right posterior teeth with maxillary sinus floor

Tooth (right)	Mean distance of root tip and maxillary sinus floor (mm)
1 <sup>st</sup> Premolar	3.50
2 <sup>nd</sup> Premolar	2.76
1 <sup>st</sup> Molar	2.49
2 <sup>nd</sup> Molar	2.27

**Table 2:** Average distances of the root apices of the maxillary left posterior teeth with maxillary sinus floor

Tooth (left)	Mean distance of root tip and maxillary sinus floor (mm)
1 <sup>st</sup> Premolar	3.95
2 <sup>nd</sup> Premolar	2.45
1 <sup>st</sup> Molar	2.25
2 <sup>nd</sup> Molar	2.04

## DISCUSSION

The vertical relationship between the maxillary posterior teeth and the floor of the maxillary sinus is of prime importance especially a cause for concern during endodontic procedures like apicectomies, extractions and implant planning. A study done by Chand et al. in 2017 on the relationship of the inferior wall of the maxillary sinus with the maxillary posterior teeth using CBCT in adult population with chronic periodontitis revealed the mean distance between maxillary molar root apices and the inferior wall of maxillary sinus was minimum for the palatal root (0.402 mm) compared to the mesiobuccal (0.932 mm), distobuccal root apices (0.903 mm) and the maxillary palatal root was found to be in close approximation to the inferior wall of maxillary antrum (12). The proximity of the root apices of the maxillary posterior teeth to the floor of the maxillary antrum followed by the measurement of buccal bone thickness using serial axial, coronal, sagittal, and paraxial cone-beam computed tomographic images was done by a study in 2015 by Kang et al. found that the apices of the mesiobuccal roots of the second molars had the shortest mean vertical distance to the maxillary sinus floor (0.18 mm) and the thickest mean horizontal distance to the buccal cortical plate (4.99 mm) among buccal roots of the three rooted maxillary molars (13). A cross sectional study was done by HaghaniFar et al. in 2018 by evaluating 160 CBCT images, where 419 molars were studied, they found that Type 2 relationship (39.1 %) was the predominant pattern, where the root was laterally projected on the maxillary sinus but its apex was found to be outside the sinus (14). Jang et al. in 2017 evaluated the probability of root fenestration or oroantral communication by the measurement of the distance from root apex to the maxillary antral floor and buccal cortex in maxillary posterior teeth by the analysis of 2182 roots of the maxillary posterior teeth from 219 CBCT images found that the palatal root apices of the maxillary first molars exhibited the highest incidence as well as the greatest mean length (1.96 mm) of protrusion into the floor of the maxillary antrum (15). Fry et al. in 2016 found that Type 0 relationship was most commonly seen in the first and second premolars and Type 1 relationship in the first and second maxillary molars. The mean distance from the floor of maxillary sinus to apex of root was found to longest for the palatal root of maxillary molars and the buccal root of maxillary first premolar while it was shortest for the mesiobuccal root of maxillary first molar and palatal root of the maxillary second premolar. The distobuccal root of maxillary second molar was found to have the greatest distance from the cortical plate (16). It is said that dental roots in the maxillary antrum are almost twice as likely to be associated with diseased sinuses than normal sinuses and even healthy teeth whose roots are inside the maxillary sinus are said to induce an inflammatory response in the sinus

membrane with dental procedures exacerbating the condition (17).

When there is a loss of teeth in the maxillary posterior region, the alveolar process undergoes a phase of remodelling. The vacant tooth socket collapses creating an edentulous space and the maxillary sinus can also undergo pneumatization further decreasing the available underlying alveolar bone which can hinder the osseointegration process of implant. Maxillary sinus floor augmentation is a surgical procedure done by lifting the lower Schneiderian membrane (sinus membrane) and placing a bone graft can increase the amount of alveolar bone in the posterior maxilla in the region of the premolar and molar teeth. Misch in 1987 devised a category for the treatment of edentulous posterior maxilla based on the amount of alveolar bone available below the maxillary antrum and the ridge width known as subantral augmentation category (SA). This category includes SA 1 where it has an adequate amount of vertical bone for implants, around 12 mm where no manipulation of sinus is required, SA2 category has 0-2 mm less than the ideal height of alveolar bone for implant placement that require surgical correction, SA3 category has just 5-10 mm of alveolar bone below the maxillary sinus and SA4 category where only 5 mm of alveolar bone is available below the maxillary sinus (18).

## CONCLUSION

The anatomical relationship of the roots of the maxillary posterior teeth with floor of the maxillary antrum is of significant importance during dental procedures like extractions, endodontic surgeries and implant planning. Hence a thorough knowledge of the anatomy and adequate precautions is required for a proper treatment planning. This was an institutional study where both the right and left maxillary sinuses were taken into consideration. In literature, there are very few studies that have assessed this vertical relationship in the Indian population, especially in the South Indian Population. The vertical measurements of all the maxillary posterior teeth (First Premolar, Second Premolar, First molar, Second molar of both right and left side) were assessed along with the different types of maxillary sinus floor configurations (Type 0, 1, 2, 3) with the roots of the maxillary posterior teeth. This vertical relationship assessment was done in both the sections of the CBCT that included the panoramic and tangential sections. The limitation of this study is a low sample size and hence a study with a larger sample size along with the evaluation of incidental findings of the maxillary sinus in the CBCT will be done in the future.

## CONFLICT OF INTEREST

Authors declare that there is no conflict of interest

## REFERENCES

1. Iwanaga, J., Wilson, C., Lachkar, S., Tomaszewski, K.A., Walocha, J.A., Tubbs, R.S. Clinical anatomy of the maxillary sinus: application to sinus floor augmentation. *Anat Cell Biol.* 2019; Vol 52(1):17-24.
2. Souza, A.D., Rajagopal, K.V., Ankolekar, V.H., Souza, A.D., Kotian, S.R. Anatomy of maxillary sinus and its ostium: A radiological study using computed tomography. *CHRISMED J Health Res.* 2016; 3:37-40.
3. Mudgade, D.K., Motghare, P.C., Kunjir, G.U., Darwade, A.D., Raut, A.S. Prevalence of anatomical variations in maxillary sinus using cone beam computed tomography. *J Indian Acad Oral Med Radiol.* 2018; 30:18-23.
4. Kumar, S.M., Reddy, G.S., Naidu, B.R., Nimkar, A.S., Deivanayagi, M., Chalapathi, K.V., and et al., Prevalence of pathologic findings in maxillary sinuses in asymptomatic patients using cone-beam computed tomography. *Ann Indian Acad Otorhinolaryngol Head Neck Surg* 2019; 3:31-37.
5. Fry, R.R., Patidar, D.C., Goyal, S., Malhotra, A. Proximity of maxillary posterior teeth roots to maxillary sinus and adjacent structures using Denta scan®. *Indian J Dent.* 2016; 7(3):126-130.
6. Estrela, C., Nunes, C.A., Guedes, O.A., Alencar, A.H., Estrela, C.R., Silva, R.G., and et al., Study of Anatomical Relationship between Posterior Teeth and Maxillary Sinus Floor in a Subpopulation of the Brazilian Central Region Using Cone-Beam Computed Tomography - Part 2. *Braz Dent J.* 2016; 27(1):9-15.
7. Gu, Y., Sun, C., Wu, D., Zhu, Q., Leng, D., Zhou, Y. Evaluation of the relationship between maxillary posterior teeth and the maxillary sinus floor using cone-beam computed tomography. *BMC Oral Health.* 2018; 18(1):164.
8. Razumova, S., Brago, A., Howijieh, A., Manvelyan, A., Barakat, H., Baykulova, M. Evaluation of the relationship between the maxillary sinus floor and the root apices of the maxillary posterior teeth using cone-beam computed tomographic scanning. *J Conserv Dent.* 2019; 22:139-143.
9. Chand, A., Ronghe, B., Byakod, G., Lathi, A.A., Muglikar, S. Relationship between inferior wall of maxillary sinus and maxillary posterior teeth using cone-beam computed tomography in healthy and chronic periodontitis patients. *J Indian Soc Periodontol.* 2017; 21:466-472.
10. Ok, E., Güngör, E., Colak, M., Altunsoy, M., Nur, B.G., Ağlarci, O.S. Evaluation of the relationship between the maxillary posterior teeth and the sinus floor using cone-beam computed tomography. *Surg Radiol Anat.* 2014; 36(9): 907-914.
11. Alqahtani, S., Alsheraimi, A., Alshareef, A., Alsaban, R., Alqahtani, A., Almgran, M., and et al., Maxillary sinus pneumatization following extractions in Riyadh, Saudi Arabia: A Cross-sectional Study. *Cureus.* 2020; 12(1):e6611.
12. Chand, A., Ronghe, B., Byakod, G., Lathi, A.A., Muglikar, S. Relationship between inferior wall of maxillary sinus and maxillary posterior teeth using cone-beam computed tomography in healthy and chronic periodontitis patients. *J Indian Soc Periodontol.* 2017; Vol 21(6):466-472.
13. Sung Hyun Kang., Bom Sahn Kim., Yemi Kim. Proximity of posterior teeth to the maxillary sinus and buccal bone thickness: A biometric assessment using Cone-beam Computed Tomography. *Journal Of Endodontics.* 2015; Vol 41(11):1839-1846.
14. Sina Haghanifar., Ehsan Moudi., Ali Bijani., Nazanin Arbabzadegan., Farideh Nozari. Relationship between the maxillary molars roots and sinus in a selected iranian population: A CBCT Study, *J Res Med Dent Sci.* 2018;6 (2):544-549.
15. Jang, J.K., Kwak, S.W., Ha, J.H., Kim, H.C. Anatomical relationship of maxillary posterior teeth with the sinus floor and buccal cortex. *J Oral Rehabil.* 2017 Aug; 44(8):617-625.
16. Fry, R.R., Patidar, D.C., Goyal, S., Malhotra, A. Proximity of maxillary posterior teeth roots to maxillary sinus and adjacent structures using Denta scan®. *Indian J Dent.* 2016; 7(3):126-130.
17. Roque-Torres, G.D., Ramirez-Sotelo, L.R., Vaz, S.L., Bóscolo, S.M., Bóscolo, F.N. Association between maxillary sinus pathologies and healthy teeth. *Braz J Otorhinolaryngol.* 2016; 82(1):33-38.
18. Tarun Kumar, A.B., Anand, U. Maxillary sinus augmentation. *J Int Clin Dent Res Organ.* 2015; 7: Suppl S1:81-93.