

Case series

Diagnostic spectrum of cysts of head and neck: Case series and review of literature

Rukma Bhandary, Deepalakshmi Tanthry, Poojitha S., Basavaprakash Sheelavanth, Meghana Udaya Acharya

Department of Otorhinolaryngology, A J Institute of Medical Sciences and Research Centre, Mangalore, Karnataka, India

(Received: November 2023 Revised: January 2024 Accepted: February 2024)

Corresponding author: **Deepalakshmi Tanthry**. Email: deepalakshmitanthry@yahoo.com**ABSTRACT**

One of the foremost problems that brings patients to Otorhinolaryngology clinics are cystic swellings in the head and neck region. We aimed to study the presentation, configuration of cystic swellings of head and neck for diagnosis and management. A retrospective study of 30 patients belonging to diverse age group and presenting with complaints of swelling in the craniofacial domain to the otorhinolaryngology outpatient department was conducted. Based on the characterization of cystic swellings of head and neck, most turned out to be usually benign. The most common cyst was epidermoid cyst (56%), followed by second arch branchial cyst (26%). A single case each of nasopalatine cyst and intra-parotid lymphatic cyst was also reported. Swellings in the head and neck can have various presentations. Cytologic examination of head and neck cysts along with pre-operative clinical examination and imaging offer imperative information concerning the nature of the cystic lesions, and may rarely lead to any misdiagnosis.

Keywords: Head and neck; cystic swellings; epidermoid cyst; thyroglossal cyst; branchial cyst; intra-parotid lymphatic cyst.

INTRODUCTION

Cystic swellings in the craniofacial region are one of the prime grievances that patients confer with to the Department of Otorhinolaryngology and Head and Neck surgery. Primary or secondary malignancies may be associated with cystic swellings. Non neoplastic lesions can occur due to infections, inflammations, congenital or developmental disorders (1). These cysts vary in the age and site of presentation. Due to the extensive array of clinically analogous and similar lesions that betide in the head and neck region, diagnostic conundrums frequently arise thereby confounding the clinical picture and management protocol (2). Clinical history and anatomical site of the lesion play a very crucial role while attempting to narrow down on the differential diagnosis of a cystic neck mass (1). Fine needle aspiration cytology has a propitious role in the management of adults presenting with cysts in the head and neck but in children this is perplexing (3). In this case series we have hypothesized the ultimate diagnosis and management strategies which were notably deceptive or unconventional in their manifestations and clinico-radiological features. Diagnostic protocol usually followed- Imaging of the swelling, fine needle aspiration cytology, excision of the swelling *in toto*.

A retrospective study which included 30 patients belonging to diverse age groups and presenting with swelling in the head and neck region to the outpatient department of Otorhinolaryngology of a tertiary medical college hospital from January 2022 to July 2023 was done. All these patients underwent excision under general anaesthesia. The age, location and mode of presentation, and the histopathological features

were reviewed and analysed in accordance with the standard protocol.

Presentation of cases**Case 1**

A 22-year-old gentleman presented with complaints of midline neck swelling. There were no complaints of pain or discharge from swelling and no pressure symptoms. On examination, a solitary 3x3cm swelling was noted in the midline of neck which moved upwards with deglutition as well as protrusion of tongue (Fig.1). Ultrasound of the neck revealed features suggestive of thyroglossal cyst. Patient underwent Sistrunk operation under general anesthesia and histopathological examination of the specimen confirmed the diagnosis of thyroglossal cyst (Fig. 2).

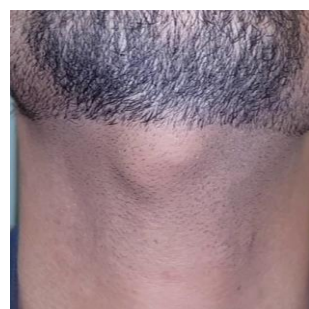


Fig. 1: Preoperative midline neck swelling

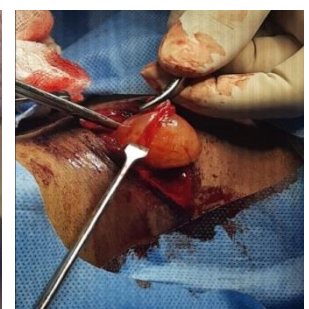

Fig. 2: Intraoperative finding

Case 2

A 23-year-old female with previous history of incision and drainage of right lateral neck abscess 2 months back presented with complaints of right sided neck swelling for 15 days. There were no other associated symptoms. Examination revealed a right lateral neck swelling measuring 4x3cm arising in front of the

anterior border of right sternocleidomastoid muscle with a healed linear scar noted over it (Fig. 3). There was no sinus or fistula and no cervical lymphadenopathy. Contrast enhanced computed tomography of neck was suggestive of right side second branchial cleft cyst. Patient underwent excision of cyst under general anesthesia (Figs. 4 & 5), old scar tissue was also excised for better cosmetics. Histopathological examination report revealed features suggestive of branchial cyst.

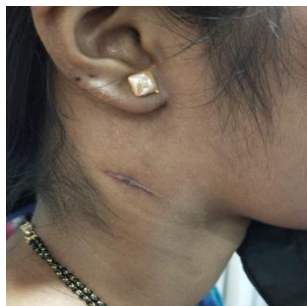

Fig. 3: Lateral neck swelling and healed scar over it

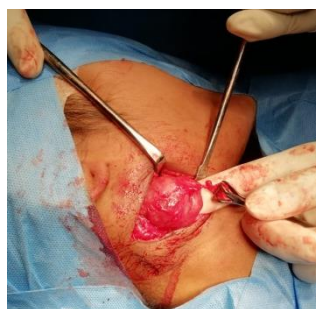

Fig.4: Intraoperative cyst

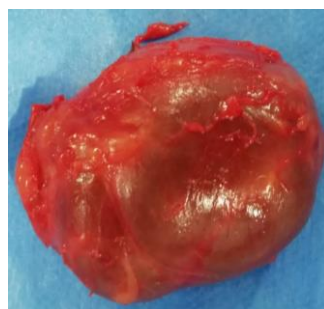


Fig.5: Postoperative cyst specimen excised *in toto*

Case 3

A female toddler of 3 years presented with a 6-month history of swelling below the right ear which was associated with pain for 15 days (Fig. 6). The swelling was insidious in onset, gradually advanced in size over six months while pain was acute in onset, initially present throughout the day and subsided on taking medications. On examination, a 6 x 5 cm solitary swelling was noted in the right preauricular region with no scars, sinus, or dilated veins. It was non tender and there was no local rise of temperature. MRI done showed an enlarged right parotid gland with thin walled multicystic and multiseptated mass involving deep and superficial lobes with few cysts showing T2 shading- likely venolymphatic malformation (Fig.7). Diagnostic and therapeutic excision of the cyst over the parotid was done under general anesthesia and histopathology of the same was suggestive of – intraparotid lymphatic cyst (Figs. 8 & 9).

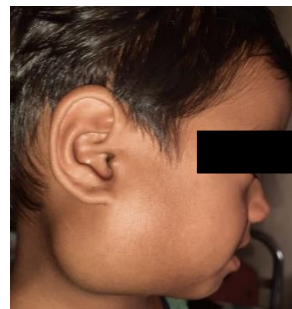

Fig. 6: 3-year-old child with infra-auricular swelling

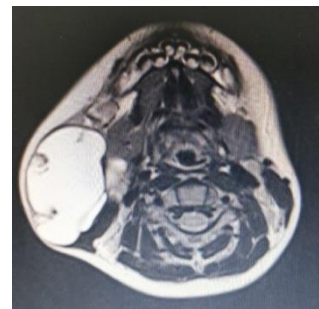

Fig. 7: Preoperative MRI showing enlarged right parotid gland

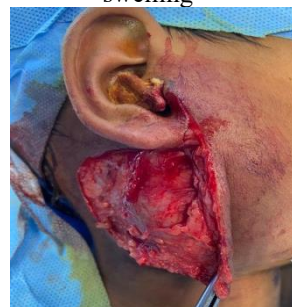

Fig. 8: Intra-operative finding

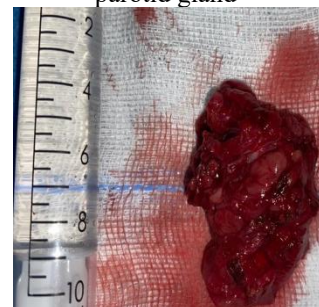

Fig. 9: Post-operative specimen

Case 4

A 19-year-old female presented with complaints of right sided neck swelling of 1 month duration, associated with pain for 1 week and one episode of fever prior to the onset of pain. On clinical examination, a 6 x 5 cm swelling was noted on the right lateral aspect of the neck, along the anterior border of the right sternocleidomastoid muscle (Fig.10). Swelling was tender on palpation and local rise of temperature was also noted. Ultrasound of neck and FNAC revealed features suggestive of branchial cyst. Pre-operatively broad-spectrum intravenous antibiotics were started along with symptomatic treatment. Patient underwent excision of the cystic mass under general anesthesia (Fig. 11). Histopathological examination was reported as hemorrhagic branchial cleft cyst.

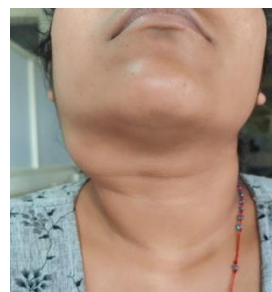

Fig. 10 Preoperative image

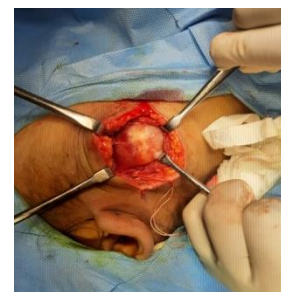

Fig. 11: Suspected branchial cyst (intraoperative)

Case 5

A 11-year-old girl child presented with a 5-year history of swelling behind left pinna. It was insidious in onset, initially 1x1cm now progressed to current size. There were no complaints of pain or discharge

from the swelling. On examination, a 4x3cm non tender cystic swelling was noted over the posterior aspect of left pinna, with smooth surface, discolored skin (Fig. 12), and no local rise of temperature. Ultrasound of the swelling suggested differential diagnoses of Epidermoid cyst or Slow flow venous malformation.

Child underwent excision under General anesthesia and cyst excised *in toto* was sent for Histopathological interpretation which was reported as- Epidermoid cyst.

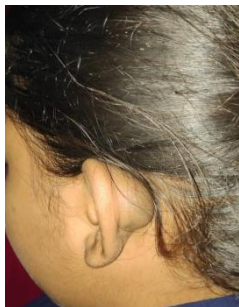

Fig. 12: 11-year-old presenting with a pinna swelling

Case 6

A 23-year-old female complained of midline neck swelling for 2 months, not associated with pain, discharge or any pressure symptoms. On examination, 2x2cm swelling was noted in the midline of the neck just above the suprasternal notch (Fig. 13) which did not move with deglutition or protrusion of tongue. Ultrasonography of Neck revealed a well-defined ovoid homogeneously iso-hyperechoic solid lesion in midline in the anterior aspect of neck- suggested FNAC for further evaluation. FNAC done revealed features of epidermoid cyst. Hence, the patient underwent excision (Fig. 14) under general anesthesia, with post operative histopathological findings also suggestive of epidermoid cyst.




Fig. 13: Epidermoid cyst in the neck

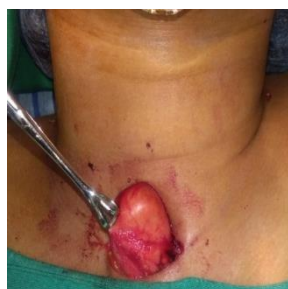

Fig. 14: Postoperative cyst

Case 7

A 8-year-old girl child presented with a right lateral neck mass of 8 months duration. Examination indicated a 6x4cm swelling just below the right ear lobule extending towards the lateral aspect of the neck, along the anterior border of the right sternocleidomastoid muscle. There was no evidence of scar/sinus/fistula. Ultrasound revealed features suggestive of the right second branchial cleft cyst. She underwent excision of the cyst under General

anesthesia and histopathological examination was reported as branchial cleft cyst (Fig. 15).

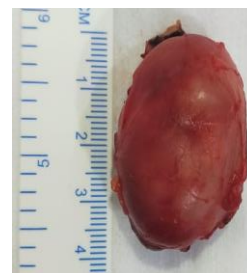


Fig. 15: Branchial cleft cyst excised *in toto*

Case 8

A 24-year-old female presented with swelling below the right ear lobe for 3 years. On examination, a 3x4cm firm, non-tender, mobile swelling was noted over the right angle of mandible region with overlying erythematous tense skin (Fig.16). There was no scar/sinus/fistula and no local rise of temperature. Ultrasound done revealed well defined cyst with thick contents in subcutaneous plane overlying right parotid- likely benign aetiology. She underwent diagnostic and therapeutic excision of the swelling which was histopathologically diagnosed as epidermoid cyst.

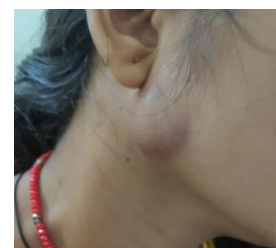

Fig. 16: Epidermoid cyst over the angle of mandible

Case 9

An elderly woman aged 52 years presented with a 2-month history of painless swelling in the oral cavity. Clinical examination showed a 3x4cm soft, fluctuant, non-tender, cystic, solitary swelling distending the right nasal ala with obliteration of nasolabial fold (Fig. 17). Partial obliteration of the right nasal vestibule was also observed. Computed Tomography showed well-defined round soft tissue lesions in the lateral pyriform aperture. *In toto* excision of cyst was done under general anesthesia via sublabial approach (Fig. 18) and a histopathological diagnosis of nasolabial cyst was established.

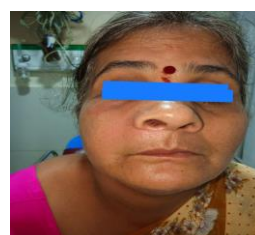

Fig. 17: Nasolabial cyst

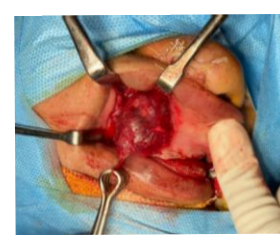

Fig. 18: Sublabial approach for nasolabial cyst

Case 10

A 46-year-old male presented with complaints of painless swelling over the nose for a duration of 3 months (Fig.19). Examination showed a 2 x 2 cm firm, non-compressible, non-tender, solitary swelling over the left side of the nasal bridge. Computed tomography of face revealed a cystic lesion over the nasal dorsum without any extension into the cranium or orbit. Patient was taken up for excision biopsy of the cyst under general anesthesia and histopathological examination of the specimen was suggestive of infected dermoid cyst (Fig. 20).

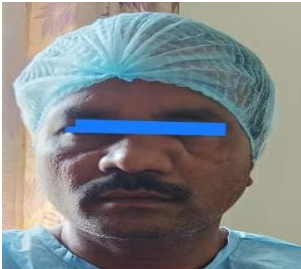

Fig.19: Cystic swelling over dorsum of nose

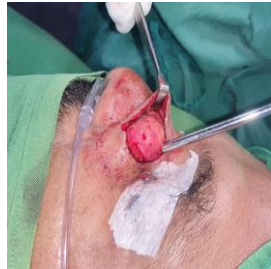

Fig. 20: Infected dermoid cyst

DISCUSSION

Patients frequently visit otorhinolaryngology clinics with cystic masses in the head and neck region. Epidermoid cysts frequently manifest as cutaneous lesions typically in the face, scalp, neck and trunk (2). From the characterization of cystic swellings of head and neck, it is found that most of them are usually benign. These cysts were predominantly found in the female population of the age group between 18 and 30 years' old. They invariably presented as an obvious visible swelling with or without any associated complaints. Swellings in the head and neck can have various aetiology, age, site and mode of presentation.

Often benign, slow-growing, and varying in size, epidermal inclusion cysts (EICs), sometimes called epidermoid cysts, can develop anywhere on the body, though they most frequently do so on the head, neck, and back (1). They classically manifest as a small nodule with evident punctum, located in the mid and lower layers of dermis (1). Infundibular portion of the hair follicle is supposed to be the origin of these cysts (1). In our study the most common cyst was found to be epidermoid cyst i.e., 56% - 17/30 cases.

Dermoid cysts can occur in any age group and have a diverse array of presentations with its location varying from brain and spinal cord to testis and ovary. It may be superficial, deep rooted or existing partly superficial and partly deep in the orbit or cranial cavity. Testis and ovaries are the most common locations in the body for occurrence of dermoid cysts while their incidence in head and neck region ranges from 1.6 to 7%, making them uncommon in this region. The lateral eyebrow is the most frequently involved site in the head and neck region, followed by

the cervical area. The orbits are involved in approximately 50% of the dermoids present in the head and neck. Out of the 30 cases in our study, only 1 case, which accounts for 3.3%, was identified as an infectious dermoid cyst located over the left lateral aspect of the dorsum of the nose.

Arising during the development of embryo, branchial cleft cysts have no gender predisposition, are characteristically seen in young patients although they can occur universally and manifest as a non-tender, compressible lesion in the neck or immediately below the mandible (1).

Branchial cleft cysts are most commonly seen abutting the internal carotid artery and adhering to internal jugular vein. Other anatomical locations include: subplatysmal plane, in the anterior triangle of neck, within the carotid sheath, and abutting the pharyngeal wall and potentially extending superiorly to the skull base (1). In our study it was found that branchial cleft cysts made up 26.6% cases – 8/30 cases. Most branchial cleft cysts are derived from the second branchial cleft; they present clinically as lateral cervical masses at the anterior border of the sternocleidomastoid muscle and are usually slow-growing (5). They may be lined by stratified squamous, pseudostratified columnar, or mixed epithelium with stroma composed of abundant lymphoid tissue (5).

The anatomical structure that serves as a connection between the initial position of thyroid primordium at foramen cecum and its final position after it descends down to the neck during the process of development is the thyroglossal duct. Failure of obliteration of thyroglossal duct may result in the formation of thyroglossal cyst. Since a thyroglossal cyst has connection to the hyoid bone or base of the tongue, its classic presentation is a non-tender mass in the anterior neck that moves with tongue protrusion (1). The most frequent congenital or developmental defect that presents as anterior cervical swelling and primarily affects the paediatric age group is the thyroglossal duct cyst. It is gender non-specific with 2nd to 5th decade of life being the mean age of presentation. In our study it was found in a young male aged 22 years with prevalence of 3.3%- 1/30 cases.

Our study also included a case of intra parotid lymphatic cyst which is a rare occurrence. The parotid gland is the preferred location for these cysts to develop, most likely because it contains intraparotid lymph nodes, which are absent in all other salivary glands (6). In HIV-positive patients, parotid cysts are typically regarded as one of the indicators of infection.

A single case of nasopalatine cyst was also included which is a developmental, epithelial, nonneoplastic, non-odontogenic cyst and known to be the most common type of non-odontogenic cysts (7).

Nasolabial cysts are also rare soft tissue cysts which often go unnoticed or are misdiagnosed and mistreated, thereby posing a major challenge to head and neck and maxillofacial surgeons. We came across one such case which was managed successfully by intra-oral surgical excision.

CONCLUSION

Cystic swellings in head and neck can have various aetiology, age, site and mode of presentation thereby posing a great challenge when it comes to diagnosing the cases. In our study we have reported the typical and atypical mode of presentation. Out of the 30 cases included, the most common cyst was found to be epidermoid cyst (56%- 17 out of 30 cases), followed by second arch branchial cyst (26%- 8 out of 30 cases). The rest consisted of thyroglossal cyst, cystic hygroma, dermoid cyst, nasolabial cyst, nasopalatine cyst and intra-parotid lymphatic cyst as described.

All the cystic swelling of head and neck were benign in nature with specific imaging and pathological features. Preoperative clinical examination and imaging are mandatory. Hence, it is imperative to excise the cyst and confirm the diagnosis histopathologically, so as to prevent recurrence or any cosmetic sequelae.

CONFLICT OF INTEREST

The authors have no conflicts of interest.

REFERENCES

1. Vazquez Salas, S., Pedro, K., Balram, A., Syed, S., Kotaka, K., Kadivar, A., *et al.*, Head and neck cystic lesions: A cytology review of common and uncommon entities. *Acta Cytologica*. 2022;66(5):359-370.
2. Dutta, M., Saha, J., Biswas, G., Chattopadhyay, S., Sen, I., Sinha, R. Epidermoid cysts in head and neck: Our experiences, with review of literature. *Indian J Otolaryngol Head Neck Surg*. 2013; 65(S1):14-21.
3. Connolly, A.A.P., MacKenzie, K. Paediatric neck masses – a diagnostic dilemma. *J Laryngol Otol*. 1997;111(6):541-545.
4. Kumar, N.G., Arora, S.S., Kumar, I., Pandher, P.K., Balwan, R. Dermoid cysts of the maxillofacial region: Case series. *J Maxillofac Oral Surg*. 2019;18(2):238-244.
5. Hsieh, Y.Y., Hsueh, S., Hsueh, C., Lin, J.N., Luo, C.C., Lai, J.Y., *et al.*, Pathological analysis of congenital cervical cysts in children: 20 years of experience at Chang Gung Memorial Hospital. *Chang Gung Med J*. 2003 Feb;26(2):107-113.
6. Joshi, J., Shah, S., Agarwal, D., Khasgiwal, A. Benign lymphoepithelial cyst of parotid gland: Review and case report. *J Oral Maxillofac Pathol*. 2018;22(Suppl 1):S91-S97.
7. AlQahtani, M., AlDossari, A., Nasser, A., AlOtaibi, K. Nasopalatine duct cyst: A diagnostic dilemma. *Dent Oral Craniofac Res [Internet]*. 2018;4(4).