

Research article

Retrospective study of 69 cases of cerebral cystic echinococcosis in patients admitted to National hospital in Bishkek city, Kyrgyzstan

Keneshbek Yrysov, Taalaybek Seyitbekov, Nurlan Mamashev, Beksultan Yrysov, Jumabek Tashibekov

Department of Neurosurgery, I. K. Akhunbaev Kyrgyz State Medical Academy, Bishkek, Kyrgyzstan

(Received: August 2023

Revised: September 2023

Accepted: October 2023)

Corresponding author: **Keneshbek Yrysov**. Email: drkeneshbekyrysov9@gmail.com

ABSTRACT

Introduction and Aim: Cystic echinococcosis (CE) is a severe, widespread parasitic sickness that continues to be a significant health concern in many countries. The goal of the study was to find out how well ozonized saline solution (O3SS) cleans hydatid cysts to improve the results of neurosurgical treatment for patients with cerebral CE and to make suggestions for preventing the disease.

Methods: This study included 69 patients with cerebral CE who were operated in our hospital. The diagnosis was confirmed at the time of the surgery, which allowed us to evaluate the data of computerized tomography in 22 (31.9%) and magnetic resonance imaging in 47 (68.1%) patients of the brain.

Results: All 69 examined patients presented with cysts of parasitic origin, which were confirmed intraoperatively. Intact removal of hydatid cysts using the Dowling-Orlando technique was performed in 43 cases (62.3%). The best exposure duration for processing residual cavities in brain echinococcosis utilizing O3SS is 10 minutes. The duration of the follow-up period ranged from 8–18 months.

Conclusion: When larvocysts of CE are exposed to 10–15 mg/l of O3SS, the germ cells go through irreversible changes in their ultrastructure that stop them from making new cysts within five minutes.

Keywords: Cerebral cystic echinococcosis; ozonized saline solution; hydatid cysts; azure B-eosin Y.

INTRODUCTION

Cystic echinococcosis (CE) is a severe, widespread parasitic sickness that continues to be a significant health concern in many countries (1, 2), including Kyrgyzstan, a hyperendemic area for hepatic echinococcosis (2, 3). The prevalence of CE has increased by two to three times, particularly among adolescents. Most patients with serious CE complications present at a medical facility at a critical stage (4–6).

One way to figure out how to effectively treat CE is to investigate the pharmacological effects of local drugs on the cyst cavity and fibrous capsules. This could stop the disease from getting worse. The recurrence rate of CE would decline, and treatment strategies would be improved. Local ozone therapy is a novel method practiced for the disinfection and treatment of parasite cysts and fibrous capsules of CE. Ozone is an effective antibacterial, antiviral, and antifungal agent that eliminates microorganisms directly by rupturing their plasma membrane, which causes them to lose their capacity to survive and proliferate (7–9). These issues are still inadequately addressed; some are still in the development phase and do not have widespread practical applications, so all the ones mentioned became the basis for the present study (10–12).

The purpose of the study was to evaluate the efficacy of ozonized saline solution (O3SS; NaCl-0.9%) in disinfecting hydatid cysts to enhance the outcomes of neurosurgical treatment in patients with cerebral CE and to provide recommendations for prevention.

MATERIALS AND METHODS

This study included 69 patients with cerebral CE who were operated on from 2004–2014 at the Neurosurgery Clinic of the National Hospital under the Ministry of Health of the Kyrgyz Republic, the clinical base of the Department of Neurosurgery, I. K. Akhunbaev Kyrgyz State Medical Academy, Bishkek, Kyrgyzstan. The diagnosis was confirmed at the time of the surgery, which allowed us to evaluate the data of computerized tomography (CT) in 22 (31.9%) and magnetic resonance imaging (MRI) in 47 (68.1%) patients of the brain. They were 46 (66.7%) females and 23 (33.3%) males. In the age group of 11–45 years, we observed 49 (71.1%) patients; in the age group of 46–60 years, there were 5 (7.2%) patients, and 15 (21.7%) patients in the age group of 61 and older. The mean age of patients was 35 years (Table 1).

Table 1: Distribution of patients according to gender and age ($p < 0.05$)

Age	Male	Female	Total
11–45 years	14	35	49 (71.1%)
46–60 years	2	3	5 (7.2%)
≥61 years	7	8	15 (21.7%)
Total	23 (33.3%)	46 (66.7%)	69 (100%)

In 22 (31.9%) of the 69 patients, the duration between the onset of symptoms and the first visit to a primary facility was up to 6 months, and in 27 (39.1%) of the patients, it was between 6 and 12 months; the remaining 20 (29.0%) patients were admitted to the clinic after a 12-month or longer period. Although

there is a wide range of clinical manifestations of the condition, it should be noted that general cerebral symptoms (caused by intracranial hypertension) and, in rare instances, seizures have been noted. It was very difficult to determine the nature of the disease solely based on clinical symptoms because there was a wide range of clinical manifestations of cerebral CE, which depended on many factors. Therefore, instrumental methods of investigation were required for the differential diagnosis, which is what we carried out in the survey process. The primary non-invasive and very informative techniques for diagnosing CE were brain MRI and CT scans, which we employed extensively during our study. The preoperative CT/MRI results were observed in 43 (62.3%) patients who had unicameral solitary cysts, 18 (26.1%) had multiple cysts, 5 (7.2%) had calcification cysts, and 3 (4.3%) had parasite cyst decay and abscess.

Table 2: Distribution of patients according to neuroimaging data (p<0.05)

Character of cysts	Number of cases
Solitary	43 (62.3%)
Multiple	18 (26.1%)
With calcification	5 (7.2%)
With decay and abscess	3 (4.3%)
Total	69 (100%)

Disinfecting of hydatid residual cyst cavity with O3SS

Under general anesthesia, a craniotomy and surface brain revision were carried out during cerebral CE surgery. O3SS was prepared right during the procedure, when the fibrous capsule, liquid, and chitin shell of the hydatid cysts were opened and removed. Next, a concentration of 10–15 mg/l of O3SS was added to the cavity, and O3SS gauze was used to backfill it. Here, the exposition lasted between 10 and 15 minutes. Then, O3SS and soaked gauze are removed.

A specially designed, light-tight container was used to produce O3SS in standard 400-ml vials. After 20 minutes at room temperature (18–20 °C), a saline ozone-oxygen mixture with a concentration of 10–15 mg/l was prepared in an ozone generator. An ozonimeter was used to measure the ozone concentration at the outlet of the ozone-oxygen mixture, which was then shown on the scoreboard. At a pressure of no more than 0.5 atm, oxygen was delivered from a cylinder by a gearbox. O3SS was added to the ozone analyzer in the liquid medium within the ozonizer housing unit, and the result was shown on the screen for five seconds. The ozone concentration was measured using the built-in machine ozonimeter in the 5 ml tube.

Collection of a sample

After the hydatid cyst was punctured using electrical suction and a needle, the fibrous capsule was taped and an echinococectomy was done. Right away,

smears were made using swabs from the chitin shell from the inner wall of the fibrous capsule (scrapings were taken from the walls of the fibrous capsule and a smear was made on a glass slide).

Specimens of hydatid liquid were prepared as follows: a liquid was collected into a 15-ml tube with a cap, centrifuged for 10 minutes at 1500 rpm, and smears on a slide were made from the resultant precipitate. The smears were immediately stained with azure B-eosin Y.

After using O3SS (NaCl 0.9%), we treated the cyst cavity to collect material for this study. These preparations were seen under a light microscope (Carl Zeiss, Germany) after being stained with azure B-eosin Y.

RESULTS

All 69 examined patients presented with cysts of parasitic origin, which were confirmed intraoperatively. In our study, 44 patients (63.8%) out of the 69 parasitic cysts were processed using O3SS. In other series, for 25 (36%) patients, we have used hypertonic saline.

Intact removal of hydatid cysts using the Dowling-Orlando technique was performed in 43 cases (62.3%). In the other 26 cases (37.7%), we removed hydatid cysts after puncture using a needle and aspiration of cyst content. At five minutes of exposition, O3SS caused destructive processes in the protoscoleces. There was swelling of the syncytial tegument layer with small recesses and perforations (Figs. 1 and 2).

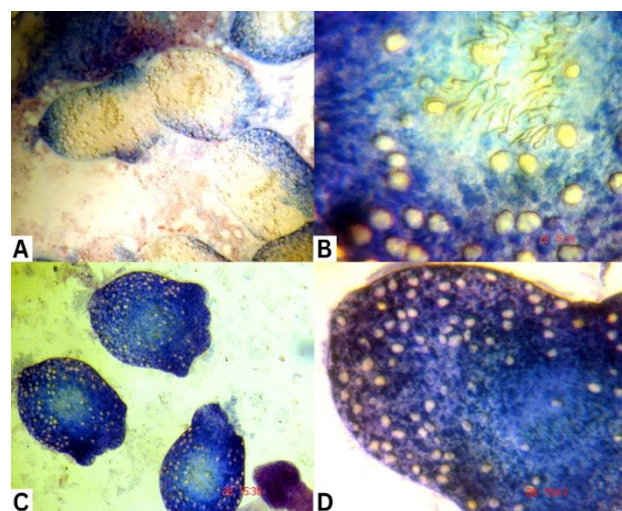


Fig. 1: Azure B-eosin Y staining demonstrated before the exposition of ozonized saline solution (x10).

Some protoscoleces shed their hooks. It was studied as a separation and destruction of the germinal protoscolecocyte membrane, as well as a reduction in the number of calcareous corpuscles and deformation of the crown of hooks. The germinal membrane cells of protoscoleces were separated from one another and vacuolated. The breakdown of cytoplasmic organelles

was observed in their cytoplasmic condensation of granular and fibrous elemental membrane structures. Following a 10-minute treatment, the lavrocyst germinal elements lost all of their cellular structure and transformed into a heterogeneous gel consisting of single clusters of dense, fine-grained material, fibrous structures that looked like osmiophil calf formed by the condensation of material from calcareous corpuscles, and fragments of the lavrocysts' exfoliated cuticular shell.

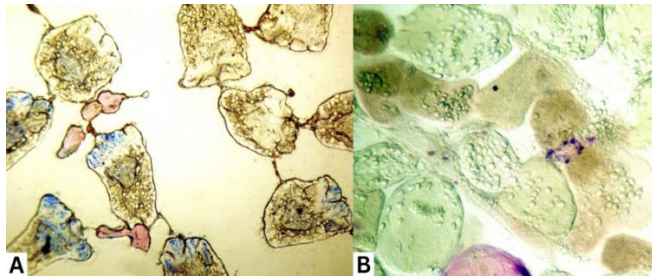


Fig. 2: Azure B-eosin Y staining demonstrated after the five-minute exposition of ozonized saline solution (x10)

It was noted that the disappearance of calcareous corpuscles, which lose regular oval forms and get rounded, smoothed out the structure of the parenchyma. Delamination of the cuticular membranes and violation of their integrity with the release of the liquid contents of the protoscolece parenchyma outward through defects of the cuticular membrane have been seen. Apparently, it can be explained by the bonding of dead protoscoleces in conglomerates (Fig. 3).

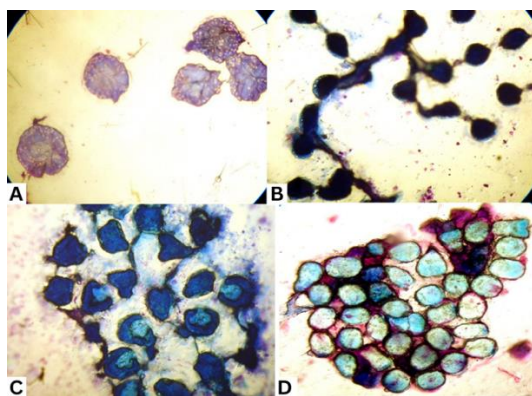


Fig. 3: Azure B-eosin Y staining demonstrated after the ten-minute exposition of ozonized saline solution (x10)

For a duration of 15 minutes, the same damaging changes in protoscoleces have been observed and maintained. So, it was shown that the germ cells of tapeworm larvocysts change in a way that lasts as soon as five minutes after being exposed to ozone. This means that they lose their ability to produce more cysts. Cellular components are completely destroyed after prolonged exposure to O3SS. Based on the aforementioned data, O3SS is highly germicidal and can be used to disinfect remaining cavities following echinococectomy. The adverse changes in protoscoleces during exposure for 10 and 15 minutes

are almost the same. As a result, the best exposure duration for processing residual cavities in brain echinococcosis utilizing O3SS is 10 minutes.

All patients received antiparasitic agents in the postoperative period for at least four weeks. Mortality after surgery was observed in three cases, two of which were 25 patients and were operated on using hypertonic saline but not O3SS. One of these patients died in the early postoperative period due to herniation caused by brain swelling. The other two patients died in the four- and six-days following surgery due to postoperative complications, including meningitis. Out of 69 cases, 26 patients with combined hydatid cysts underwent thoracic (9 cases) and abdominal (17 cases) surgery.

The duration of the follow-up period ranged from 8 to 18 months. Each patient who has survived has shown improvement in their overall health and neurological function. Out of the 25 patients who operated on hypertonic saline, 5 (7.2%) experienced a recurrence of the hydatid disease. The range of the mean recurrence time was 6 to 8 months. In 44 patients treated with O3SS, there was no recurrence. In four individuals, seizures were noted as postoperative complications.

DISCUSSION

The larval form of the tapeworm *Echinococcus granulosus* which causes CE, manifests as a hydatid cyst. It is a zoonotic illness that is common all throughout the world, particularly in rural regions where sheep and cattle are domesticated (1–6).

When it comes to radiologically diagnosing hydatid cysts, MRI and CT scans are still the most common types of examination (10). MRI is significant for preoperative evaluation and surgical planning. When a person has a hydatid cyst, CT scans show a well-defined, spherical or ovoid, hypodense, non-enhancing cystic lesion without pericystic edema (13, 14). On MRI, it frequently appears hyperintense with a hypointense halo around the cyst on the T-2 weighted image and hypointense on the T-1 weighted image (15).

Currently, the most effective treatment option available globally is surgical extirpation. The most often used surgical method is the Dowling-Orlando technique. This highlights the safe evacuation of the unruptured cyst. If the cyst is infected and widespread adhesions form to the surrounding brain parenchyma, this might not be feasible. This is an essential stage in the delivery of the intact cyst. The surgeon must have sufficient patience to rely on the hydrostatic pressure of the saline solution that is flushed into the cavity. Lowering the head of the patient also makes it easier for the cyst to come out by gravity (16). As intraoperative cyst rupture is the most frequent and dangerous complication, any tension on the cyst wall

at any stage should be avoided, as it may further result in parasite dissemination, severe inflammatory or allergic reactions, and many local cyst recurrences can be observed (17, 18). Hypertonic saline should be utilized for disinfecting the cavity after an intraoperative cyst rupture (19, 20). The use of O3SS in this study showed high efficacy in disinfecting the cyst cavity.

Albendazole should be used to sterilize the cyst, lower the risk of anaphylaxis, decrease the tension in the cyst wall, and lower the recurrence rate, even though surgery remains the only choice for managing cerebral hydatid cysts (12, 21).

Preventing the parasite from spreading can help manage CE. Limiting the areas where dogs are allowed and preventing animals from consuming meat infected with cysts are a couple of preventive measures. These basic precautions need to be taken: keeping stray dog numbers under control; prohibiting home slaughter of sheep and other animals; avoiding consuming any food or drink that may have been contaminated by dog feces; and preventing dogs from grazing on the corpses of infected sheep. Hands should be washed with soap and warm water after touching pets and before handling food. Emphasize to kids the need for hand washing as a means of preventing infections.

CONCLUSION

When larvocysts of CE are exposed to 10–15 mg/l of O3SS, the germ cells go through irreversible changes in their ultrastructure that stop them from making new cysts as soon as five minutes after ozonizing. Extended exposure to O3SS results in a 100% breakdown of all cellular components. Since ozone is a potent antiparasitic, it can be used to disinfect remaining cavities and stop CE from recurring.

ACKNOWLEDGEMENT

This paper was proofread and edited for clarity by Nobuyuki Hamajima, Chief and professor in the Department of Healthcare Administration of the Nagoya University Graduate School of Medicine, Nagoya, Japan.

CONFLICT OF INTEREST

The authors declare no conflicts of interest.

REFERENCES

1. Ismail, M. A., Al-Dabagh, M. A., Al-Janabi, T. A., Al-Moslih, M. I., Al-Ani, M. S., Rassam, S., *et al.*, The use of computerised axial tomography (CAT) in the diagnosis of hydatid cysts. *Clin Radiol.* 1980;31(3):287-290.
2. Von Sinner, W. N. Radiographic, CT and MRI spectrum of hydatid disease of the chest: a pictorial essay. *Eur Radiol.* 1993;3:62-70.
3. Toktogaziev, B., Omorov, K., Aitbaev, S., Artisbekov, B., Omorov, R., Vityala, Y., *et al.*, A rare case of concurrent pulmonary and hepatic hydatid cysts treated by single-stage surgical management. *Clin Case Rep.* 2022; 10(5): e05897.

4. Toktogaziev, B., Aitbaev, S., Abdiev, A., Toktosunov, A., Rysova, A., Imankulov, M., *et al.*, Role of videolaparoscopy in the surgical treatment of hepatic cystic echinococcosis. *Biomedicine.* 2022;42(6):1268-1271.
5. Bahloul, K., Ouerchefani, N., Kammoun, B., Boudouara, M. Z. Unusual brain edema caused by an intracranial hydatid cyst: Case report and literature review. *Neurochirurgie.* 2009; 55(1):53-56.
6. Douabi, I., Aoufi, S., El Amrani, J., Sabri, M., Agoumi, A. Cerebral hydatidosis. *Med Trop (Mars).* 2008;68(2):110.
7. Brodowska, A. J., Nowak, A., Śmigielski, K. Ozone in the food industry: Principles of ozone treatment, mechanisms of action, and applications: An overview. *Crit Rev Food Sci Nutr.* 2018; 58:2176-2201.
8. Re, L. Ozone in Medicine: A Few Points of Reflections. *Front Physiol.* 2022;13:842229.
9. Viebahn-Haensler, R., León Fernández, O. S. Ozone in Medicine. The low-dose ozone concept and its basic biochemical mechanisms of action in chronic inflammatory diseases. *Int J Mol Sci.* 2021;22(15):7890.
10. Senapati, S. B., Parida, D. K., Pattajoshi, A. S., Gouda, A. K., Patnaik, A. Primary hydatid cyst of brain: Two cases report. *Asian J Neurosurg.* 2015;10(2):175-176.
11. Kartikueyan, R., Patel, S. M., Chattopadhyay, A., Krishnan, P. Primary cerebral hydatid cyst: An unusual cause of very slowly progressive hemiparesis in a child. *J Neurosci Rural Pract.* 2016;7(4):603-604.
12. Wang, J., Cai, B., You, C. Surgical treatment options for cerebral alveolar echinococcosis: experience in six patients. *Neurol India.* 2009;57(2):157-161.
13. Furtado, S. V., Visvanathan, K., Nandita, G., Reddy, K., Hegde, A. S. Multiple fourth ventricular hydatidosis. *J Clin Neurosci.* 2009;16(1):110-112.
14. Gana, R., Skhissi, M., Maaqili, R., Bellakhdar, F. Multiple infected cerebral hydatid cysts. *J Clin Neurosci.* 2008; 15(5):591-593.
15. Izci, Y., Tüzün, Y., Seçer, H. I., Gönül, E. Cerebral hydatid cysts: technique and pitfalls of surgical management. *Neurosurg Focus.* 2008;24(6):E15.
16. Kayacan, S. M., Vatanserver, S., Temiz, S., Uslu, B., Kayacan, D., Akkaya, V., *et al.*, Alveolar echinococcosis localized in the liver, lung and brain. *Chin Med J (Engl).* 2008;121(1):90-92.
17. König, C., Claussen, C. *Echinococcus cysticus*. *Rofo.* 1997; 167(4):M31.
18. Nepalia, S., Joshi, A., Shende, A., Sharma, S. S. Management of echinococcosis. *J Assoc Physicians India.* 2016;54:458-462.
19. Reddy, D. R. Managing cerebral and cranial hydatid disease. *Neurol India.* 2009;57(2):116-118.
20. Takci, E., Sengul, G., Akar, A., Uslu, H., Alper, F., Erdogan, F., *et al.*, Alveolar echinococcosis of the brain in five patients. *J Clin Neurosci.* 2008;15(10):1105-1109.
21. Tappe, D., Weise, D., Ziegler, U., Müller, A., Müllges, W., Stich, A. Brain and lung metastasis of alveolar echinococcosis in a refugee from a hyperendemic area. *J Med Microbiol.* 2008;57(Pt 11):1420-1423.