

Case report

The diagnostic challenge of gastrointestinal tuberculosis mimicking colon cancer: A case reportYethindra Vityala¹, Gulnura Turdumambetova², Jun Yi Lim³, Nestan Moidunova⁴, Elnura Usubalieva², Altynai Baitelieva², Vipin³¹Department of Pathology, International Higher School of Medicine, International University of Kyrgyzstan, Bishkek, Kyrgyzstan²Department of Phthysiology, I. K. Akhunbaev Kyrgyz State Medical Academy, Bishkek, Kyrgyzstan³I. K. Akhunbaev Kyrgyz State Medical Academy, Bishkek, Kyrgyzstan⁴National Center of Phthysiology, Bishkek, Kyrgyzstan

(Received: June 2023 Revised: June 2023 Accepted: July 2023)

Corresponding author: **Yethindra Vityala**. Email: yethindravityala10@gmail.com**ABSTRACT**

Gastrointestinal tuberculosis (TB) accounts for 3.5% of extrapulmonary TB cases and is associated with active or inactive pulmonary TB in 76% of cases. A 53-year-old lady with no prior history of morbidity visited our hospital's department with weakness, an inability to eat, a 39°C fever, no chills, and night sweats that had been present for about six months. Additionally, a colonoscopy revealed a mamelonated mass of a stenotic character in the ascending colon, along with minor mesenteric adenitis, on computed tomography scans of the abdomen and pelvis. The obtained specimen's histological analysis revealed histiocytes and a few large cells producing granulomas without neoplastic features. The colonic biopsy's Löwenstein-Jensen medium culture revealed development of the Mycobacterium TB complex. After receiving therapy for two months with rifampicin, isoniazid, pyrazinamide, and ethambutol, followed by four months with rifampicin and isoniazid, the patient had significantly improved. The current case serves as an example of the difficulty in diagnosing GI TB. The lack of symptoms and occasionally false-positive imaging results reinforce the necessity for increased clinical suspicion.

Keywords: Gastrointestinal tuberculosis; neoplasm; computed tomography; colonoscopy; antitubercular therapy.**INTRODUCTION**

Gastrointestinal tuberculosis (TB) accounts for 3.5% of extrapulmonary TB cases and is associated with active or inactive pulmonary TB in 76% of cases (1–4). In the abdomen, the most affected areas are the GI tract (50%), the peritoneum (43%), and the mesenteric lymph nodes (8%) (5), with GI involvement typically occurring after lymphatic or hematogenous spread from an active pulmonary focus or miliary TB. The ascending, transverse, descending, and sigmoid colons, as well as the anorectum, are the most impacted parts of the intestine (75%), followed in decreasing order by the ileocecal and jejunoileal areas (6). The ascending colon was implicated in this case report, which is unusual and presents a diagnostic problem. Despite its high prevalence, it can be difficult to diagnose GI TB since both the common symptoms and diagnostic tests lack specificity (7).

We present a case of GI TB in a person who had tested HIV-negative and had been admitted for investigation of a febrile syndrome with significant weight loss.

Case presentation

A 53-year-old lady who had no prior medical history visited our hospital's department complaining of weakness, lack of appetite, a 39°C fever, no chills, and night sweats that had been occurring for nearly six months. In the past, approximately six months after the start, pasty diarrhea and vile-smelling, black feces

were noticed for a month before stopping on their own. Additionally, she reported losing 10 kg during this time, going from 56 kg to 46 kg (20% of her total weight). The results of the physical examination were normal. HIV testing revealed that the patient was not infected.

Mammography and upper GI endoscopy were normal. Centrilobular nodules were visible in both upper lobes of the chest on a computed tomography (CT) scan. This was associated with persistent granulomas in the right and lower upper lobes on the opposite side, calcified mediastinal lymph nodes, and widespread consolidation in the left upper lobe. The patient had a bronchoscopy with a collection of bronchoalveolar lavage, a direct examination of microorganisms and cultures, and a quick molecular test for TB; all of them were negative in view of the pulmonary findings despite the absence of symptoms.

A CT scan of the abdomen and pelvis revealed ileocolic parietal thickening with mild mesenteric adenitis (Fig. 1). A colonoscopy was done to further clarify the situation, and the results indicated a mamelonated mass of a stenotic nature in the ascending colon that was restricting the lumen without enabling sight of its proximal limits (Fig. 2).

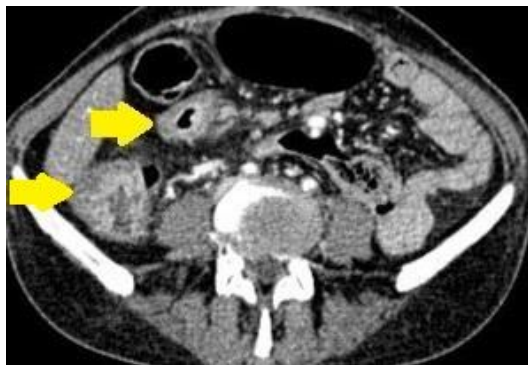

Fig. 1: CT of the abdomen and pelvis showed ileocolic parietal thickening

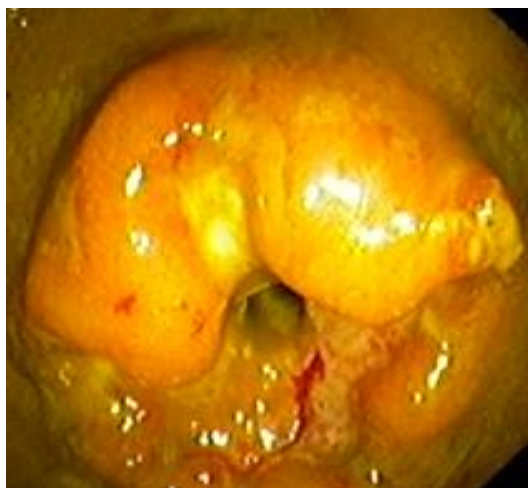

Fig. 2: Colonoscopy showing a mamelonated mass of a stenosing nature in the ascending colon

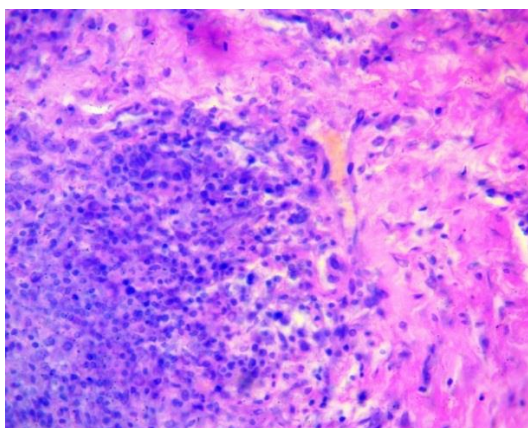


Fig. 3: Hematoxylin and eosin staining demonstrating Langhans giant cells, epithelioid cell granulomas, and caseous necrosis (x40)

The obtained specimen's histological analysis revealed histiocytes and a few large cells producing granulomas devoid of neoplastic features (Fig. 3). A reassessment with barium enema examinations revealed multiple nodular colonic filling defects. The colonic biopsy's Löwenstein-Jensen medium culture revealed the development of the *Mycobacterium TB* complex.

The patient received rifampicin, isoniazid, pyrazinamide, and ethambutol as part of the standard TB therapy regimen for two months, then four months of rifampicin and isoniazid. The patient gained weight and became afebrile throughout follow-up. Following

the medication, the patient showed a significant improvement, gaining weight and no longer experiencing any diarrhea or low-grade fever.

DISCUSSION

Ingestion of infected sputum or milk, hematogenous spread from other foci, lymphatic spread, and dissemination to neighboring organs all contribute to the development of GI TB (8). Typically, symptoms are nonspecific, such as abdominal pain, weight loss, anorexia, and fever (7), as they can affect multiple abdominal organs while sparing the lung, necessitating a high index of suspicion for diagnosis (9).

GI TB can present clinically similarly to other conditions such as inflammatory bowel disease, colon cancer, and GI infections (10). Some cases are described in which the endoscopic appearance of the lesions initially led to the suspicion of a neoplasm (11). Additionally, the imaging results may be difficult to identify, making histopathology necessary in some cases (12). CT is useful in identifying ascites, lymphadenopathy, hepatosplenomegaly, and asymmetries of the ileocecal area (5). The most effective diagnostic method is colonoscopy, along with ileoscopy. The lesions, which include ulcers, strictures, and pseudopolyps, might appear more than once and in various places. In this instance, the symptoms were nonspecific, the radiological examinations were inconclusive, active pulmonary TB was excluded, and the colonoscopy revealed a lesion suggestive of a tumor.

GI TB is still challenging to diagnose since the paucibacillary lesions are frequently inaccessible (11). There is no gold standard test for diagnosis; however, radiological, endoscopic, and surgical procedures, as well as microbiological and histopathological examinations of the acquired samples, can all be used (13). CT of the abdomen and pelvis is the diagnostic modality of preference for assessing the extent and type of abdominal injury, and the findings are quite diverse and not very specific, including intestinal wall thickening, ulcerations, fibrosis, stenosis, lymphadenopathy, and peritoneal implants (7, 13).

Smear microscopy with Ziehl-Neelsen staining and culture with Löwestein-Jensen staining are two microbiological tests with limited sensitivity that have the drawback of requiring 4-6 weeks to provide results and having the potential to produce false positives (14). Polymerase chain reaction may also provide reliable results due to its high sensitivity, which is greater than that of smear microscopy and culture, and specificity (>85%), with the added benefit of producing results more quickly (15). In this instance, hematoxylin-eosin staining revealed lesions with Langhans giant cells, epithelioid cell granulomas, and caseous necrosis; non-caseous necrosis and a nonspecific chronic inflammatory infiltration were uncommon in only 20% of patients (14). Due to the

difficulties in making the diagnosis, significant clinical suspicion is required, and each patient's workup must be customized, beginning with less invasive investigations (13).

The preferred course of treatment is a six-month course of anti-tuberculosis medication, which includes two months of rifampicin, isoniazid, pyrazinamide, and ethambutol and four months of rifampicin and isoniazid. Surgical intervention should be reserved for patients who develop complications; it should always be deferred. With anti-tuberculosis medication, most patients' colonic lesions will disappear, and follow-up colonoscopy is not necessary if they become asymptomatic.

CONCLUSION

The current case serves as an example of the difficulty of diagnosing GI TB. Due to the absence of specific symptoms and the presence of potentially misleading imaging results, the need for a high level of clinical suspicion is increased.

CONFLICTS OF INTEREST

The authors declare no conflicts of interest.

REFERENCES

1. Burrill, J., Williams, C. J., Bain, G., Conder, G., Hine, A. L., Misra, R. R. Tuberculosis: a radiologic review. *Radiographics*. 2007; 27(5):1255-1273.
2. Rathi, P., Gambhire, P. Abdominal tuberculosis. *J Assoc Physicians India*. 2016;64(2):38-47.
3. Vityala, Y., Zhumabekova, A., Dzhumakova, C., Tagaev, T., Namazbekova, A., Djanaliev, B. Fine-needle aspiration cytology-based accurate and rapid diagnosis of breast tuberculosis mimicking an abscess. *Clin Case Rep*. 2021;9(11):e05104.
4. Vityala, Y., Zhumabekova, A., Tagaev, T., Kurmanalieva, A., Mukashova, A., Begaliev, B. Congenital miliary tuberculosis in a neonate born to a mother diagnosed with tuberculosis after delivery. *Indian J Lepr*. 2021;93:135-138.
5. Horvath, K. D., Whelan, R. L. Intestinal tuberculosis: return of an old disease. *Am J Gastroenterol*. 1998;93(5):692-696.
6. Alvares, J. F., Devarbhavi, H., Makhija, P., Rao, S., Kottoor, R. Clinical, colonoscopic, and histological profile of colonic tuberculosis in a tertiary hospital. *Endoscopy*. 2005;37:351-356.
7. Abu-Zidan, F. M., Sheek-Hussein, M. Diagnosis of abdominal tuberculosis: lessons learned over 30 years: pectoral assay. *World J Emerg Surg*. 2019;14:33.
8. Schmidt-Lauber, C., Jacobi, J., Polifka, I., Hilgers, K. F., Wiesener, M. S. Suspected colonic cancer turns out to be disseminated tuberculosis in a kidney transplant recipient: A case report. *Medicine (Baltimore)*. 2019;98:e16995.
9. Debi, U., Ravisankar, V., Prasad, K. K., Sinha, S. K., Sharma, A. K. Abdominal tuberculosis of the gastrointestinal tract: revisited. *World J Gastroenterol*. 2014;20:14831-14840.
10. Shreshtha, S., Ghuliani, D. Abdominal tuberculosis: A retrospective analysis of 45 cases. *Indian J Tuberc*. 2016;63:219-224.
11. Shinga, B. W., Dièye, A., Badiane, N. M. D., Lakhe, N. A., Diallo, V. M. C., Mbaye, K. D., et al., Intestinal tuberculosis revealed by acute bowel obstruction during paradoxical reaction to antituberculosis treatment in an immunocompetent

patient: about a case and literature review. *Pan Afr Med J*. 2019;32:173.

12. Schmidt-Lauber, C., Jacobi, J., Polifka, I., Hilgers, K. F., Wiesener, M. S. Suspected colonic cancer turns out to be disseminated tuberculosis in a kidney transplant recipient: A case report. *Medicine (Baltimore)*. 2019;98:e16995.
13. Fahlbusch, T., Braumann, C., Uhl, W. Treatment of abdominal tuberculosis: Background, diagnostics, and treatment of a global problem. *Chirurg*. 2019;90:818-822.
14. Misra, S. P., Misra, V., Dwivedi, M., Gupta, S. C. Colonic tuberculosis: clinical features, endoscopic appearance and management. *J Gastroenterol Hepatol*. 1999;14:723-729.
15. Almadi, M. A., Ghosh, S., Aljebreen, A. M. Differentiating intestinal tuberculosis from Crohn's disease: a diagnostic challenge. *Am J Gastroenterol*. 2009;104:1003-1012.