

Research article

The reliability of TIRADS classification in predicting thyroid malignancy based on ultrasound findings in Mosul city

Abeer Wali Ahmed¹, Saad Muwafaq Attash¹, Mohammad Harith Mohammad Zacki Al Saaty²

¹Department of Surgery, College of Medicine, Ninevah University, Mosul, Iraq

²Department of Medicine, College of Medicine, Mosul University, Mosul, Iraq

(Received: March 2022 Revised: July 2022 Accepted: July 2022)

Corresponding author: **Abeer Wali Ahmed**. Email: abeerwali82@gmail.com

ABSTRACT

Introduction and Aim: Ultrasound of the thyroid gland is a routine procedure. Nodules are the most common disorders seen and analyzed by ultrasound. The study purpose was to show how accurate ultrasonography was at identifying benign from malignant nodules using (Thyroid Imaging Reporting and Data System TIRADS) categories. High-frequency ultrasonography scanning of the neck and thyroid glands offers useful information and anatomical images.

Materials and Methods: This study involved 495 patients who were subjected to a thyroid ultrasound imaging from December 2019 to December 2020. The ultrasound and evaluation was performed by a professional Radiologist by means of a transducer with linear-array (between 5 - 12 MHz) (DC-30, Shenzhen Mindray Bio-Medical Electronics Co., Ltd). Nodules detected were evaluated for composition, echogenicity, boundary, shape and echogenic foci. Each attribute was recorded using the standardized scoring system provided by the ACR Thyroid Imaging Reporting and Data System (ACR TI-RADS). The scores obtained, were used in classifying the nodules as TI-RADS 1, 2, 3, 4a, 4b, and 5 to define risk levels of malignant nodule.

Results: TIRADS approach was used to assess the thyroid ultrasound data obtained and the nodules categorized created on ultrasound features such as irregular edges, shape, tall rather wide, hypo echogenic, calcified, and vascular. The TIRAD 3 category was the most common accounting for about 251 cases (52.73 percent of the calculated diagnostic results, which included specificity (50%), sensitivity (96.59%), positive (97.21%) and negative (55.17%) predictive values. The study revealed 26 (4.25%) of the nodules to be cancerous.

Conclusion: Since the TIRADS system of categorization is a good technique for predicting malignancies in thyroid nodules, we employ ultrasound as the first diagnostic tool for efficiently finding and classifying thyroid nodules.

Keywords: Thyroid malignancy; benign nodule; ultrasound; ACR TIRADS; fine-needle aspiration biopsy (FNAB).

INTRODUCTION

A thyroid nodule is a small abnormal mass or lump in the thyroid gland, the prevalence of which is extremely common. Ultrasound of the thyroid gland is commonly used to detect nodules on thyroid. Earlier studies have revealed that only about 10% of nodules of thyroid are cancerous (1,2) and a thyroid ultrasound detects thyroid nodules in 50%-70% of patients (3-5). High-frequency ultrasound scanning of the neck and thyroid glands provides useful information and anatomical images, but it also shows more gland enlargement than is visible on clinical examination.

Although computed tomography (CT), magnetic resonance imaging (MRI), and positron emission tomography (PET) are used in determining the degree of retrosternal stenosis and, in rare cases, recurring goiters (6); ultrasonography is still the most effective method for detecting nodules. In 2009, Horvath *et al.*, (7) proposed an ultra-sonogram reporting system for thyroid nodules referred as TI-RADS (Thyroid Imaging Reporting and Data System) in line with the

Breast Imaging Reporting and Data System (BI-RADS) (8,9). Further, in 2011 Kwak *et al* (5) added a subtype to this classification referred as ACR TI-RADS (American College of Radiology-Thyroid Imaging Reporting and Data System) to reduce thyroid nodule biopsies and increase overall diagnosis accuracy. The ACR-TIRADS includes a standardized scoring system based on ultrasonography features of thyroid nodules (10), useful to radiologists in diagnosis and follow up treatments. In the ACR-TIRADS each lesion is scored based on five qualitative features of the ultrasound findings which include nodule echogenicity, construction, margins, figure and foci of echogenicity (11). Further, a score for each category is based on a point score option which are summed up to provide a final score (TR score) which quantifies the risk level of each lesion as benign (TR1, 0 points), not suspicious (TR2, 2 points), mildly suspicious (TR3, 3points), moderately suspicious (TR4, 4-6 points) (TIRADS 4a low suspicion 2-10% risk for malignancy, while 4b suspicion of malignancy 10->50%). and highly suspicious (TR5, ≥7 points). Nodules with TR3-TR5

scores is suspected as malignancy risk and recommended for a fine needle aspiration biopsy.

MATERIALS AND METHODS

This study involved 495 patients who were subjected to a thyroid ultrasound imaging. The study investigation was undertaken from December 2019 to December 2020 and involved patients referred by a thyroid surgeon and endocrinologist of a private clinical facility at Mosul, Iraq. Each patient with neck hyperextended and in supine position was subjected to thyroid imaging both in the transverse and longitudinal planes. The thyroid gland ultrasound and evaluation were performed by a professional Radiologist by means of a transducer with linear-array (between 5 - 12 MHz) (DC-30, Shenzhen Mindray Bio-Medical Electronics Co., Ltd). Nodules if present were evaluated for echogenicity, construction, figure, margin, and foci of echogenicity. Each attribute was scored using the standardized scoring system provided by the ACR Thyroid Imaging Reporting and Data System (ACR TI-RADS) (11). In case more than one nodule, each was scored separately and the one with the highest TIRAD score was considered (12). Based on the cumulative scores obtained, the classification of nodules such as per TI-RADS 1, 2, 3, 4(a, b), and 5. The higher the scoring higher was the likelihood of malignancy.

The data collected was subjected to statistical analysis. The significant differences between the groups was analyzed by chi-square exact test using the SAS-9 program.

RESULTS

Our study included 495 patients. The thyroid nodule detected by ultrasound in each patient was classified by TIRADS characteristics. Majority (261 cases; 52.71%) of the nodules detected were categorized as TI-RADS 3. The other TI-RADS observed were TI-RADS 1 (23 cases, 4.65%), TIRADS 2 (74 cases;14.9%), TI-RADS 4a (108 cases; 21.82%), TI-RADS 4b (28 cases; 5.66%), and TIRADS 5 (1 case; 0.20%). Histologically, the risk of malignancy was investigated. There was an association between benign and malignant nodules (P value <0.01) from

TI-RADS 3 to 5 (Table 1; Fig1). Histologically, 26 (4.25%) nodules were malignant.

TIRADS 1 and 2, 97 thyroid nodules (19.60%) had benign sonographic features: 5/97 thyroid nodules as simple cyst, nodules with non-continuous homogeneous peripheral calcification 4/97, thyroid nodules with central cysts 8/97, spongiform were 80/97, Based on their ultrasound criteria, thyroid nodules have (0-2) score. For these thyroid nodules (FNA) done (n = 13), histopathological inspection after surgery (n =20) and followed up by ultrasound one year at least (n = 64) did not show malignancy. So, these 97 thyroid nodules were categorized as TI-RADS 1 and 2 (Table 2).

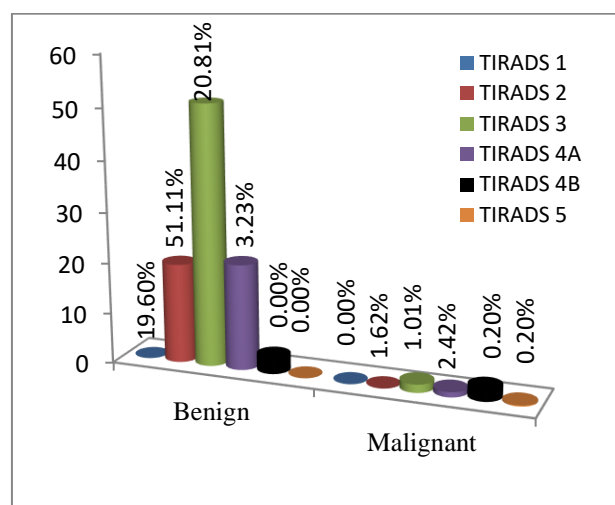


Fig.1 Percent prevalence of each TIRADS type in the study population

Among the 261 thyroid nodules detected by ultrasound imaging 253 (96.93%) nodules were negative for signs of malignancy tested, such as hyperechoic nodules and presence of tiny cystic abnormalities. The nodules were found to be hard due to merging with peripheral vascular wall and macrocalcifications. Only 8 (3.07 %) of the 261 TNs were found to be malignant by histology. Additional exams (FNA (n =50) and/or pathological outcome after surgery (n =29) clinical and ultrasound examinations performed even after one year (n = 174) revealed no malignancy. These nodules were categorized as TIRADS 3 nodules based on TI-RADS classification (5,7).

Table 1: Percentages of TIRADS types detected by ultrasound in this study

TI-RADS Type	Number (%)	Thyroid nodule type		Chi ² value
		Benign (%)	Malignant (%)	
TI-RADS 1	23 (4.65)	23 (100.00)	0	80.60**
TI-RADS 2	74(14.95)	74 (100.00)	0	
TI-RADS 3	261(52.73)	253 (96.94)	8 (3.07)	
TI-RADS 4a	108(21.82)	103(95.37)	5 (4.63)	
TI-RADS 4b	28(5.66)	16 (57.14)	12 (42.86)	
TI-RADS 5	1(0.20)	0	1 (100.00)	
Total	495	469	26	

** High significant (P < 0.01) difference between groups.

For malignant samples Chi² value =5.65, which was not statistically significant (P<0.01)

Of the 108 thyroid nodules categorized as TI-RADS 4a only 5 (4.63%) were observed to be pathologically malignant but having a <10% risk of malignancy (Table 1). Similarly, among TI-RADS 4b 28 thyroid nodules had a score of 2 with a malignancy risk of 10-50%, while 12 (2.42%) were seen to be malignant Table (1). The 12 malignant TI-RADS 4b nodules were confirmed as malignant by histopathology (Table 3). A score of 3 or higher thyroid nodules were categorized as TI-RADS 5 only 1\495 was confirmed histologically as malignant (Table 3).

Table 2: Percentage of each ultrasonography criteria in each TIRADS

TIRADS	Number (%)	Chi ² value
TIRADS 1,2	97(19.64)	
Simple cyst	5 (5.15)	171.24**
TNs with a central cyst	8 (8.25)	
TNs with non-interrupted homogeneous calcification	4 (4.12)	
Spongiform	80 (82.47)	
TIRADS 3	261(52.82)	
Malignant confirmed by histology	8 (3.07)	299.96**
Normal	253 (96.93)	
TIRADS 4	136 (27.53)	
4a	108 (79.41)	47.06**
4b	28(21.59)	

** Highly significant difference (P < 0.01) between groups.

Table 3: TIRADS classes based on histopathology

TIRADS	Histopathology		Total (%)
	Benign	Malignant	
1,2, 3, 4a	453	13	466 94.14%
4b, 5	16	13	29 (5.86%)
Total	469 (95.75%)	26(4.25%)	495

DISCUSSION

Thyroid gland disorders are frequent in modern society, demanding some standardized techniques to deal with diagnosis and care. In this study, we relied on TIRADS reporting of thyroid US findings as a simple technique to distinguish between malignant and benign thyroid nodules in any categorization. In this study, malignant risk was raised from TIRADS three to five. These results appear to be identical to Horvath's and Parallel (13, 14). Horvath recommended risk of malignancy in < 5% malignant for TIRADS 3, 5% - 10% for TIRADS 4A, 10% - 80% for TIRADS 4B and >80% malignancy for TIRADS 5 (7). If only one sonographic result is found, respectively the positive predictive value, negative predictive value, sensitivity, and specificity

prediction values are: 97.21%, 55.17%, 96.59%, 50.0%.

It appears that tall, ill-defined periphery, clear hypo echogenicity, and microcalcifications, which were the most information-giving parameters in the case of nodule malignancy, are more important than wide, ill-defined periphery, clear hypo echogenicity, and microcalcifications. The US ways of diagnosis represents the most efficient way in regards of diagnosing nodules with malignancies. This study has three limitations:

1. We used ultrasonography to examine the ultrasonography features of biopsied nodules.
2. The malignant nodules appeared to be few.
3. The information on the benign nodules could not be collected due to ethical concerns (3).

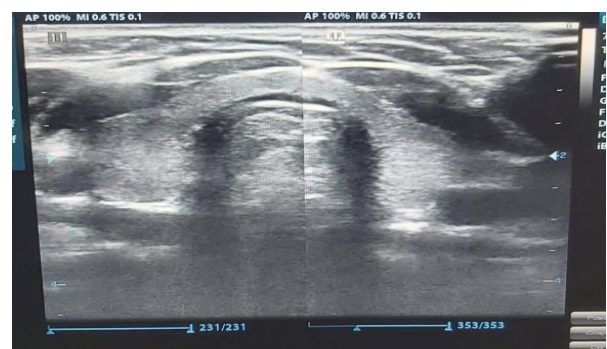


Fig. 2: Ultrasound image of a normal thyroid gland

There was no focal lesion in category 1 of the TI-RADS categorization and appeared normal (Fig 2) with homogenous thyroid tissues, while nodules (19.64 %) in this study were classified as TIRADS 2 and had benign criteria on Us, which was verified by histology such as (simple cyst, nodule with peripheral wall calcification, solid nodule with central cystic component and spongiform shape) Fig 3.

In this study the occurrence of malignant TI-RADS 3 type was 3.07% (Table 1) which is in agreement with earlier studies where the occurrence of malignancy among TI-RADS 3 was reported to be <5% (5,7). Although, many TI-RAD3 type thyroid nodules are known to result in tumors, in this study, a malignant tumor is not only uncommon but also an unexpected result of nodular goiter surgery. TI-RADS category 4 classification, TNs with a score of 4-6 consider as 4 (20.81%; Fig 5). In such a case, (5) stated that the malignancy ratio could be fifty to ninety-five percent.

The TNs with high score were classified as a TI-RAD5. In this research all the TNs studied by the ultrasound technique proved to be malignant on histopathology but (7) and (5) stated that this category can have 85-99% malignancy probability (Fig.6).

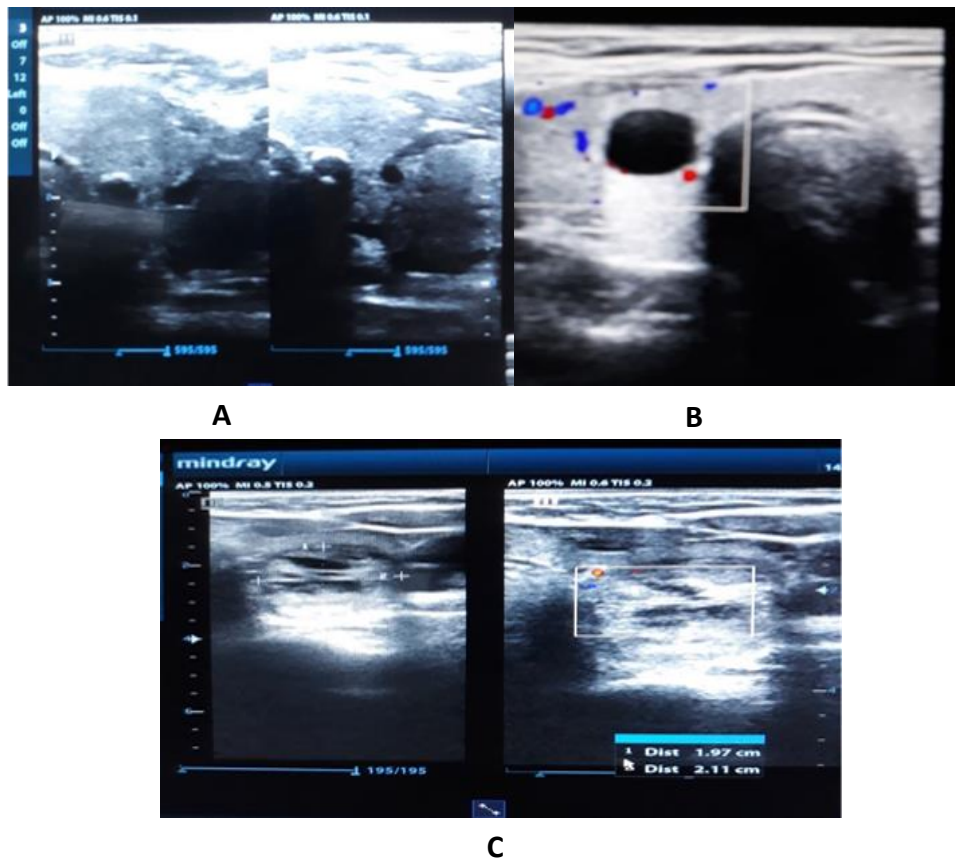


Fig.3: Ultrasound features of TI-RADS 2 nodule: A: simple cystic thyroid lesion
B: nodule with homogeneous peripheral calcification C: spongiform nodule.

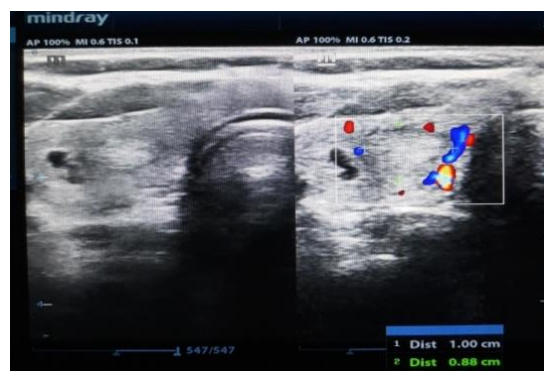


Fig. 4. Ultrasound image of TI-RADS 3 hyperechogenic nodule with vascular periphery wall

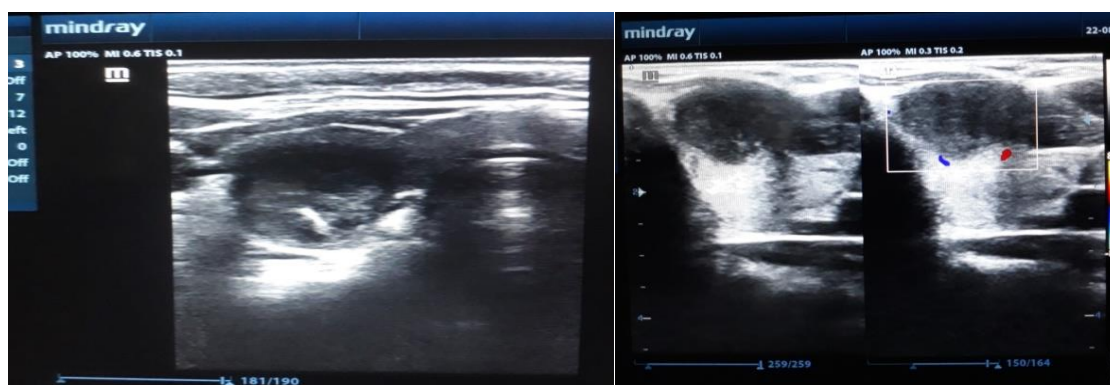


Fig. 5: TI-RADS4 showing hypoechoic nodule and punctate echogenic foci, but normal in shape with abnormal wall vascularity. Score of 5

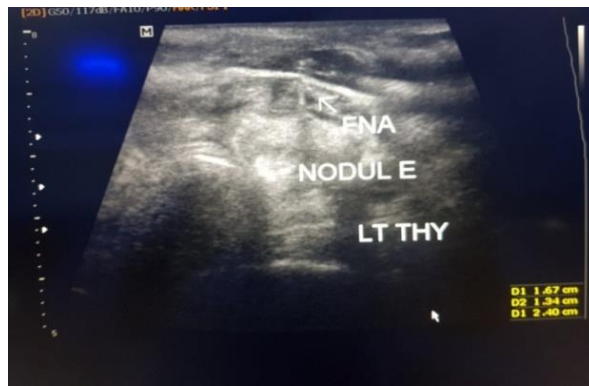


Fig. 6: TI-RADS 5 nodule with calcifications, irregular margins and the shape being rather tall than wide, invading surrounding parenchyma. Score of 8

Some US characteristics, such as hypo echogenicity and a form that is taller than wide, with uneven contours and calcifications, indicate the existence of malignancies (5, 14, 15).

The well-known effect of iodine deficiency plays a significant role in explaining the disparities in prevalence by increasing the no. of benign nodules but not the malignant nodules (16). The proportion of Magnetization transfer contrast (MTC) among thyroid malignancies is unaffected by iodine intake (17- 24), the malignant range in this study was 5%, which was still within the previous range of 1.4-15.7.

CONCLUSION

We can infer that TIRADS categorization is accurate in predicting thyroid cancer. We recommend utilizing these methods since they are dependable, simple to use, and facilitate communication between clinical specialists.

ACKNOWLEDGEMENT

The authors acknowledge the help received from people who were involved in the study.

CONFLICT OF INTEREST

Authors declare no conflict of interest.

REFERENCES

1. Koike, E., Yamashita, H., Noguchi, S., Murakami, T., Ohshima, A., Maruta, J., *et al.*, Effect of combining ultrasonography and ultrasound-guided fine-needle aspiration biopsy findings for the diagnosis of thyroid nodules. *Eur J Surg.* 2001; 167:656-661.
2. Papini, E., Guglielmi, R., Bianchini, A., Crescenzi, A., Taccogna, S., *et al.*, Risk of malignancy in nonpalpable thyroid nodules: predictive value of ultrasound and color-Doppler features. *J Clin Endocrinol Metab.* 2002; 87(5):1941-1946.
3. Hoang, J.K., Lee, W.K., Lee, M., Johnson, D., Farrell, S., US Features of thyroid malignancy: pearls and pitfalls. *Radiographics.* 2007; 27(3): 847-860.
4. Kim, K.M., Park, J.B., Kang, S.J., Bae, K.S., Ultrasonographic guideline for thyroid nodules cytology: single institute experience. *J Korean Surg Soc.* 2013;84(2):73-79.
5. Kwak, J.Y., Han, K.H., Yoon, J.H., Moon, H.J., Son, E.J., Park, S.H., *et al.*, Thyroid imaging reporting and data system for US features of nodules: a step in establishing better stratification of cancer risk. *Radiology*, 2011; 260(3):892-899.
6. Bulstrode, C.J., O'Connell, P.R., Bailey & Love's short practice of surgery. 2008. Crc Press.
7. Horvath, E., Majlis, S., Rossi, R., Franco, C., Niedmann, J.P., Castro, A., *et al.*, An ultrasonogram reporting system for thyroid nodules stratifying cancer risk for clinical management. *J Clin Endocrinol Metab.* 2009; 94(5): 1748-1751.
8. Liberman L, Menell J.H .Breast imaging reporting and data system (BI-RADS). *Radiol Clin North Am.*2002; 40(3):409-430.
9. Burnside, E.S., Sickles, E.A., Bassett, L.W., Rubin, D.L., Lee, C.H., Ikeda, D.M., *et al.*, The ACR BI-RADS® experience: learning from history. *J Am Coll Radiol.*2009; 6(12):6:851-860.
10. Tessler, F.N., Middleton, W.D., Grant, E.G., Hoang, J.K., Berland, L.L., Teefey, S.A., *et al.*, ACR Thyroid Imaging, Reporting and Data System (TI-RADS): White Paper of the ACR TI-RADS Committee. *J Am Coll Radiol.* 2017; 14 (5): 587-595.
11. Grant, E.G., Tessler, F.N., Hoang, J.K., Langer, J.E., Beland, M.D., Berland, L.L., *et al.*, Thyroid ultrasound reporting lexicon: White Paper of the ACR Thyroid Imaging, Reporting and Data System (TIRADS) Committee. *J Am Coll Radiol* 2015;12: 1272-1279.
12. Middleton, W.D., Teefey, S.A., Reading, C.C., Langer, J.E., Beland, M.D., Szabunio, M.M., *et al.*, Multiinstitutional analysis of thyroid nodule risk stratification using the American College of Radiology Thyroid Imaging Reporting and Data System. *Am J Roentgenol.*2017; 208 (6): 1331-1341
13. Ito, Y., Miyauchi, A., Inoue, H., Fukushima, M., Kihara, M., Higashiyama, T., *et al.*, An observational trial for papillary thyroid microcarcinoma in Japanese patients. *World J Surg.*2010; 34(1):28-35.
14. Russ, G., Royer, B., Bigorgne, C., Rouxel, A., Bienvenu-Perrard, M.,Leenhardt, L. Prospective evaluation of thyroid imaging reporting and data system on 4550 nodules with and without elastography. *Eur J Endocrinol.* 2013; 1;168(5):649-655.
15. Kim, E.K., Park, C.S., Chung, W.Y., Oh, K.K., Kim, D.I., Lee, J.T., *et al.*, New sonographic criteria for recommending fine-needle aspiration biopsy of nonpalpable solid nodules of the thyroid. *Am J Roentgenol.*2002; 178(3):687-691.
16. Solymosi, T., Tóth, G.L., Gál, I., Sajgó, C. and Szabolcs, I. Influence of iodine intake on the diagnostic power of fine-needle aspiration cytology of the thyroid gland. *Thyroid.*2002; 12(8):719-723.
17. Hahm, J.R., Lee, M.S., Min, Y.K., Lee, M.K., Kim, K.W., Nam, S.J., *et al.*, Routine measurement of serum calcitonin is useful for early detection of medullary thyroid carcinoma in

- patients with nodular thyroid diseases. *Thyroid*.2001; 11(1):73-80.
18. Lee, T.I., Yang, H.J., Lin, S.Y., Lee, M.T., Lin, H.D., Braverman, L.E., *et al.*, The accuracy of fine-needle aspiration biopsy and frozen section in patients with thyroid cancer. *Thyroid*.2002; 12(7):619-626.
 19. Segovia, I. Gomez, H. J. Gallowitsch, E. Kresnik, G. Kumnig, I. Igerc, S., *et al.*, Descriptive epidemiology of thyroid carcinoma in Carinthia, Austria: 1984–2001. Histopathologic features and tumor classification of 734 cases under elevated general iodination of table salt since 1990: population-based age-stratified analysis on thyroid carcinoma incidence. *Thyroid* .2004; 14(4):277-286.
 20. Fukushima, M., Ito, Y., Hirokawa, M., Miya, A., Kobayashi, K., Akasu, H., *et al.*, Excellent prognosis of patients with nonhereditary medullary thyroid carcinoma with ultrasonographic findings of follicular tumor or benign nodule. *World J Surg*.2009; 33(5):963-968.
 21. Trimboli, P., Ulisse, S., Graziano, F.M., Marzullo, A., Ruggieri, M., Calvanese, A., *et al.*, Trend in thyroid carcinoma size, age at diagnosis, and histology in a retrospective study of 500 cases diagnosed over 20 years. *Thyroid*.2006; 16(11):1151-1155.
 22. Baloch, Z.W., Sack, M.J., Yu, G.H., Livolsi, V.A., Gupta, P.K., Fine-needle aspiration of thyroid: an institutional experience. *Thyroid*.1998; 8(7):565-569.
 23. Deandrea, M., Ragazzoni, F., Motta, M., Torchio, B., Mormile, A., Garino, F., *et al.*, Diagnostic value of a cytomorphological subclassification of follicular patterned thyroid lesions: a study of 927 consecutive cases with histological correlation. *Thyroid* .2010; 20(10):1077-1083.
 24. Del Rio, P., Minelli, R., Cataldo, S., Ceresini, G., Robuschi, G., Corcione, L., *et al.*, Can misdiagnosis in pre-operative FNAC of thyroid nodule influence surgical treatment?. *J Endocrinol. Invest*.2011; 34(5):345-348.