

Research article

Chest CT findings and experience in 100 COVID19 patients in Mosul city, Iraq

Abeer Wali Ahmed¹, Rasha Nadeem Ahmed¹, Mohamed Muyaser Naif¹, Mohammed Tahseen Yahya², Khalid Salih Maulood², Ghassan Basil Alchalabi², Ahmed Ghiath Mohammed²

¹Surgical Department, Lecturer of radiodiagnosis, University of Ninevah, Mosul, Iraq

²Radiologist in Directorate health of Ninevah, Mosul, Iraq

(Received: July 2021

Revised: August 2021

Accepted: August 2021)

Corresponding author: Abeer Wali Ahmed. Email: abeer.ahmed@uoninevah.edu.iq

ABSTRACT

Introduction and Aim: Due to lack of PCR kits in our area, as well as the extensive dissemination and peaking of COVID-19 since March 2020, our knowledge as radiologists has become increasingly relevant for recognizing CT patterns in order to diagnose and isolate COVID-19-infected patients. In 100 instances, the investigation began with the most prevalent CT chest abnormalities and the CT severity score index in relation to sex. The goal of this study is to better diagnose COVID-19-related lung injuries, enhance the diagnostic accuracy of chest CT scans, and track disease development in Mosul City.

Materials and Methods: From June 2020 to January 2021, one hundred patients were enrolled in this cross-sectional study in Mosul, with 71 males (71%) and 29 females (29%) ranging in age from 15 to 85 years, mean SD (53.2317.80). Non contrast chest CT were done as part of investigation tool on patients were suspected COVID-19 infection.

Results: A radiologist gathered data between 4 and 10 days after the onset of symptoms and evaluated it for lesion pattern, location, and severity. The commonest CT changes (ground glass opacity 55.23%, consolidation 17.44%, broncho vascular thickening 9.88%, crazy paving 5.81% and tree in bud 5.23%) were seen, along with less common pattern (bronchiectasis 1.74%, nodules 2.33%, reversed halo sign and pleural effusion 1.17%), and no lymphadenopathy were seen. Multilobe involvement was detected in 52/100 instances (68.92%), while peripheral affection was seen in 52/100 cases (65%). The higher CT severity score 4 and 5 with male gender were found to have a significant link (P value 0.002).

Conclusion: CT pulmonary are useful as a physician's helper for management and as an excellent predictor of disease severity and patient outcome. In patients with COVID-19 positive infection, the CT scan severity score is highly linked to laboratory findings, hospital stay, and oxygen demands.

Keywords: Computed tomography; ground glass opacity; consolidation; COVID 19.

INTRODUCTION

COVID-19 is a disease caused by the SARS-CoV-2 virus, and it will be declared a pandemic (1) by the World Health Organization (WHO) in March 2020. It was initially described in China (2, 3). While in Iraq, the first case confirmed with infection by COVID -19 was certified on February 24, 2020, and since then, a torrent of cases has appeared, totaling over 1400 on April 15, 2020. (4), For diagnosing COVID -19, need evaluation of viral specific gene materials in the samples gathered from patient's blood, nose and or respiratory system secretion, while sensitivity of this test will affect validity (5) such as in Fang *et al.*, (6) because of many factors as prepared sample and controlling quality. As a result, readily available equipment such as chest x-rays and thoracic CT scans provide useful information to clinicians (7-11). Many patients with positive chest CT findings, or even those without a clinical picture of COVID -19 (e.g., fever and cough) but positive CT findings, were isolated and hospitalized in China, where they completed their lab tests. As a result, the imaging

findings are a gold standard in preventing virus transmission and controlling COVID-19. For diagnosing positive and negative specimens, computed tomography (CT) of the chest showed sensitivity of 97 % and 75 %, respectively, whereas specificity was only 25 % (12). New investigations on the influence of COVID-19 on CT scans of the chest have developed a unique scoring system that can predict the patient's death (13).

MATERIALS AND METHODS

One hundred patients were enrolled in this cross-sectional study in Mosul, at IBN Sina and Alkhansaa teaching hospitals, ranging in age from 15 to 85 years, with a mean \pm SD (53.23 \pm 17.80) and 71 males (71%) and 29 females (29%) respectively. From the beginning of June 2020 until the end of January 2021, the research was conducted. Patients had symptoms, and a chest CT was performed between 4 and 10 days after the onset of the symptoms as part of the inquiry. The most common symptoms were fever, cough, dyspnea, headache, sore throat, myalgia, arthralgia, and vomiting in 2 of

the patients. Table 1 shows 53 patients with a history of chronic illness (1).

Table 1: Percentage of patients with a history of chronic or systemic diseases

Diseases	No	%	Sig.
Cardiac disease	1	1.89	0.01
Systemic hypertension	14	26.42	
Diabetes mellitus	9	16.98	
Renal failure	3	5.66	
Cancer	2	3.77	
Bronchial asthma	15	28.3	
Multiple Disease	9	16.98	

Imaging technique

A 64-multi-slice high-resolution chest CT scan (Philips Ingenuity and Philips Brilliance 64) was performed. The following parameters were used: tube current was 110-280mA, voltage was 100-120 KV, pitch was 1.375, and the FOV was 350-400 mm. the thickness of image was between 1.25 -2.5 mm. There was no intravenous contrast medium used. With full inspiration and in a supine position, a scan of the chest was obtained from the neck to the end of the diaphragm.

Imaging analysis

Ground glass opacity GGO, crazy paving look, consolidation, broncho vascular thickening, tree in bud appearance, bronchiectasis, cavitation, and pulmonary nodules were among the observations documented by five radiologists with a combined 10 years of expertise. Then it's divided into unilateral, bilateral, central, and peripheral involvement, with upper, middle, and lower lobe involvement as subcategories. The severity method was evaluated based on the amount of lung involvement for all patients, and each lobe was given a score visually ranging from 1 to 5.

- score 1:(<5%) lobar involvement.
- score 2;(5-25%) lobar involvement.
- score 3:(26-50%) lobar involvement.
- score 4:(51-75%) lobar involvement.
- score 5:(> 75%) lobar involvement.

The score will then be the sum of each individual score, which will be out of 25 (total score collection), and the total involved lung will be determined by multiplying the total score by four.

- Participate consent and ethical approval.
- personal data were collected in this study.
- Nineveh medical college in Mosul approved the study.
- All participants or their relatives gave their permission.
- Because this is a rare, high-risk condition, our medical research ethics committee gave verbal

consent to reduce the danger of virus infection and minimize unnecessary interaction with positive individuals.

Inclusion criteria

1. Patients having one or more of the symptoms listed above (fever, cough, SOB, and sore throat) as well as positive CT pulmonary findings.
2. COVID 19 infected patients with a positive history of recent contact and positive CT pulmonary results.
3. All patients' PCR findings were available.

Exclusion criteria

1. Less than 15-year-old patients.
2. Patients who loss follows up.
3. Patients with high motion artifacts and suboptimal HRCT scan.
4. Negative RT-PCR test.

Statistical analysis

The collected data were tabulated and analyzed using SPSS and SAS. The link between CT severity score and patient gender was investigated using categorical correlation analysis.

RESULTS

This study included 100 symptomatic COVID-19 infection patients (71 male and 29 female), ranging in age from 15 to 85 years (53.23±17.80). Data was collected on age, sex, positive risk factors or chronic disease, O2 requirement or not, admission to ICU, hospital stay, and clinical outcome (alive or dead).

CT severity index correlation with sex

There was a positive link between CT severity score finding and male gender in our study (p value 0.002, severe cases out of 8 patients with score 4 and 3 out of 3 patients with score 5, severe lung CT involvement were male gender, table 2 and fig. 1.

Table 2: Comparison between patient sex and CT severity index in patients with positive COVID -19 pulmonary infections

CT score	Female	Male	Total	P value
< 5%	3 (1.45)	2 (3.55)	5	0.002**
2(6-25) %	17 (16.53)	40 (40.47)	57	
3(26-50) %	8 (7.83)	19 (19.17)	27	
4(51-75) %	1 (2.32)	7 (5.68)	8	
5(>75) %	0 (0.00)	3 (2.13)	3	
Total	29 (29)	71 (71)	100	
	0.001**			

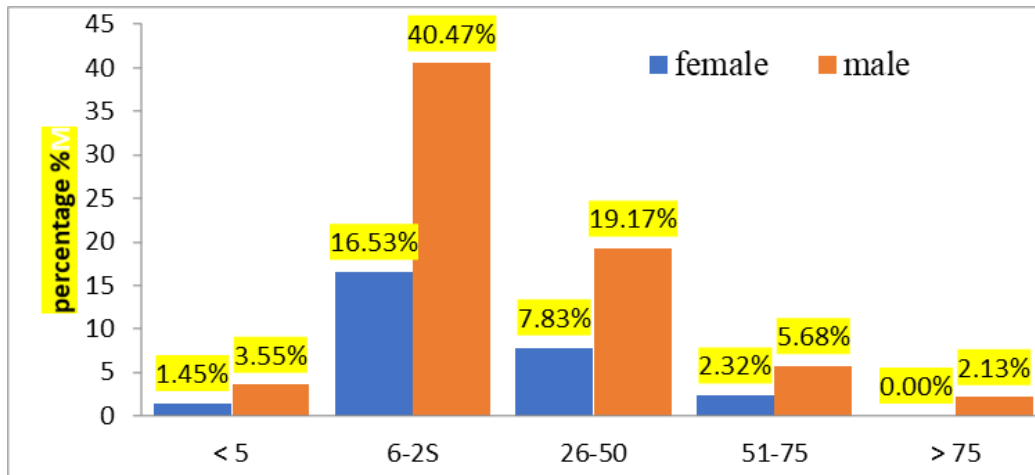


Fig. 1: Gender distribution within each CT index score.

-Fever, dyspnea, cough, sore throat, and myalgia, arthralgia, and vomiting are common symptoms in patients.

- A total of 53% of those with chronic diseases included: diabetes, hypertension, heart illness, renal impairment, cancer, bronchial asthma, and other diseases are all on the table (1).

- Out of 100 patients, 74 (74%) did not require any oxygen support. The remaining 26 patients (26%) required oxygen in the following ways: 13 patients (13%) used a nasal cannula, 10 patients (10%) used a face mask, and 3 patients (3%) used positive airway pressure (BiPAP).

- Only 20 patients out of 100 required ICU admission, with a male majority of 18/20. (90 %).

CT pulmonary changes

Ground tissue opacity was detected in 95 patients (55.23 %), and pulmonary consolidation was found in 30 patients (17.44 %), broncho vascular thickening in 17patient(9.88%), crazy paving appearance in 10 patient(5.81%) tree in bud appearance was detected in 9 patient(5.81%), less commonly pulmonary nodules in 4 patient(2.33%), bronchiectasis in 3 patient(1.74%), pulmonary effusion in 2 patient(1.17%),and reversed halo sign was found in 2 patient(1.17%) also, while no mediastinal lymph node was seen (Fig. 2-5 and table 3)

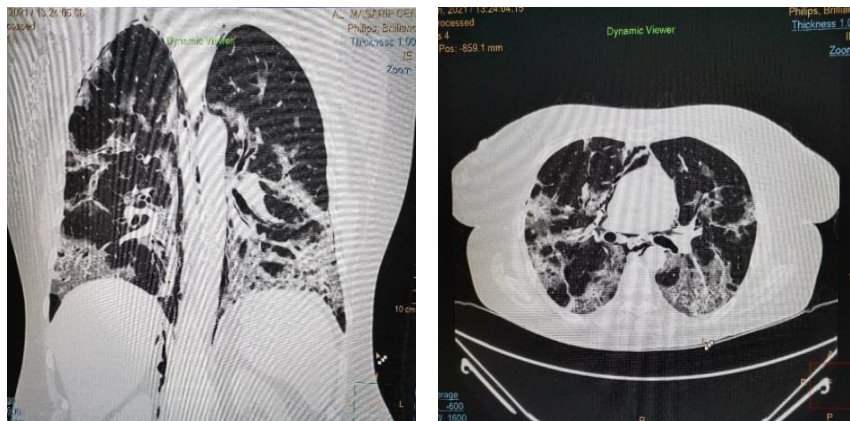


Fig. 2: Coronal and axial CT scans of a 30-year-old man with COVID-19. Exhibiting uneven consolidation, bizarre pavement pattern, dispersed GGO, and pneumomediastinum

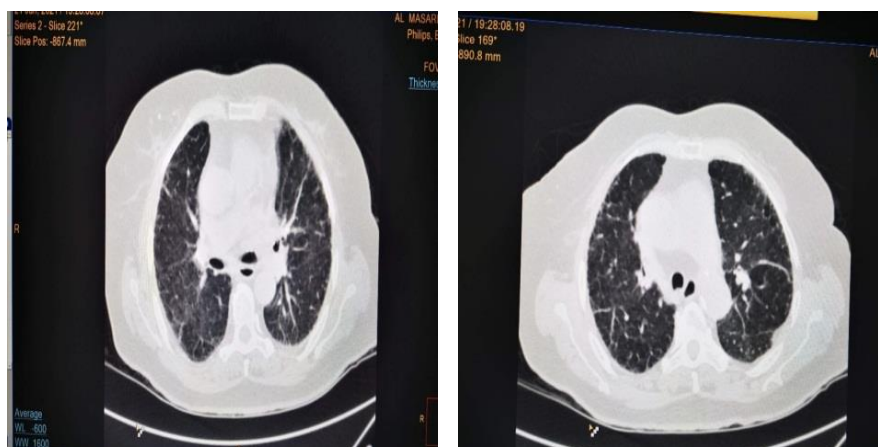
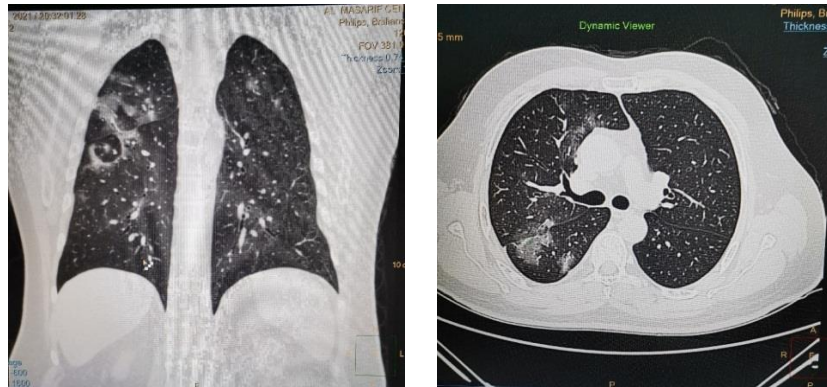
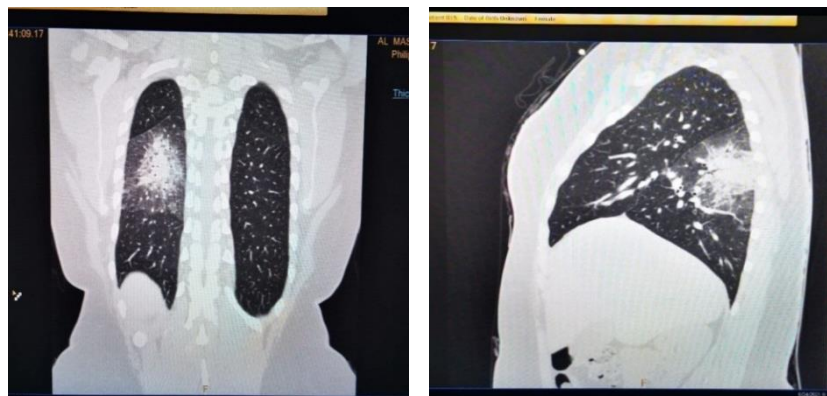


Fig. 3: Axial CT scan images of a 20-year-old Covid -19 patient, revealing septal and broncho vascular thickening.

Table 3: The chest CT pattern in patients with positive COVID 19

Lesion pattern	Percentage %
GGO	55.23
Consolidation	17.44
Broncho -vascular thickening	9.88
Crazy paving pattern	5.81
Tree bin bud appearance	5.23
Bronchiectasis	1.74
Nodules	2.33
Pleural effusion	1.17
Reversal halo sign	1.17
Mediastinal lymph node	0.00
Total	100


Fig. 4: Coronal and axial CT scan Images of a 40-year-old man with peripheral and perihelia GGO with broncho vascular thickening

Fig. 5: Coronal and axial CT scan pictures of a 27-year-old man with COVID-19, demonstrating uneven consolidation with an air bronchogram and a GG halo on the apical portion of the right lower lobe.

Pulmonary changes distribution

There were more bilateral than unilateral alterations (85%).

Involvement of the peripherals and the spread of pulmonary alterations (52 patients). The distribution of 65% was more common than the central distribution (8 patient) 10%, with a diffuse pattern (20 patients) accounting for 25% (Table 4)

Table 4: Lesion distribution within parenchyma

Distribution pattern	No. of patients	%	Significance
Peripheral	52	65	0.01
Central	8	10	
Diffuse	20	25	

In terms of lobar distribution, isolated lower involvement (10 patients 10.81%) was found to be

more common than middle lobe (8 patients 13.51%) and upper lobe (5 patients 6.76%), whereas multilobe distribution was detected in 52 patients (68.92%) with a significant value of 0.01 (Table 5).

Table 5: Percentage of affected lobes

Affected lobe	No. of patients	%	Significance
Upper	5	6.76	0.01
Lower	10	10.81	
Middle	8	13.51	
Multi Lobe	52	68.92	

In this study 53 \100 patients with comorbidities found to have a higher CT score index and more diffuse lobar involvement in comparison with other who were no comorbidities, systemic hypertension was found in 14\100 patients (26, 42%), the most

common comorbidity among these patients, and cardiac disease was found in only 1100 patients (1.89%), the rest on comorbidities as mentioned in table 1.

DISCUSSION

From June 2020 to January 2021, a multicentric cross sectional study was conducted in Mosul city, Iraq, on 100 patients who had a positive PCR test and were symptomatic, with a male predominance of 71 males (71%) and 29 females (29%) in the age range of 15 to 85 years, with a mean SD (53.23 ± 17.80). WHO advised to use CT pulmonary imaging as part of work up in diagnosing COVID-19 disease whenever PCR kits do not exist as in our city. Clinicians and radiologist should hand in hand exertion is mandatory for proper diagnosing COVID-19 infection (14). The base of our study was on visual inspection for all 5 lobes of the lung, and then the severity was further rated as score of 1 to 5 using either visual methods or a deep algorithm that uses a particular program to verify the affection of lung volume % (15-17). For better results, this problem is best solved by seeking the advice and suggestions of an experienced radiologist. The severity was higher in males, which could be due to a variety of factors such as male behavior and estrogen, which acts as a protective factor in females. (18), The existence of a risk factor or chronic illness such as cancer, lung disease, or systemic hypertension carries extremely unfavorable prognostic factors, with even worse outcomes reported when numerous diseases are discovered (19). The most common pattern of lung changes in this investigation was ground glass opacity, which was detected in (55.23 %). This was similar to other studies, such as Parry *et al.* (19), Omar *et al.* (20), and Sultan *et al.*, (21), where ground glass abnormalities were the most common CT pattern in their studies. Consolidation was found as (17.44%) in our study; Omer *et al.* (20) found similar tendency in 23 % of his study participants. Multilobe affection was detected on (68.92%), which indicates that the disease is progressing faster than unilobed involvement. Peripheral lung involvement was found on (65%), which is consistent with another research (21,8). In the current investigation, the radiologist found that pleural effusion was uncommon (1.17 %), and no lymphadenopathy was found, which could indicate bacterial infection if seen with pleural effusion or nodules (21).

CONCLUSION

In this study, it was discovered that the changes on CT scan of the chest in COVID-19 patients in Mosul city are not that different from those in other countries, in terms of pattern, lobe of distribution, and severity to be more in male gender, indicating that CT scan plays an important role in diagnosing, managing, and predicting the outcome of this viral disease.

CONFLICT OF INTEREST

There is no conflict of interest among authors.

REFERENCES

1. World Health Organization. Laboratory biosafety guidance related to coronavirus disease (COVID-19): interim guidance, 13 May 2020. World Health Organization; 2020.
2. Zhu, N., Zhang, D., Wang, W., Li, X., Yang, B., Song, J., *et al.*, A Novel Coronavirus from Patients with Pneumonia in China, 2019. *N Engl J Med.* 2020; 382(8): 727-733.
3. Guan, W. J., Ni, Z. Y., Hu, Y., Liang, W. H., Ou, C. Q., He, J. X., *et al.*, Clinical Characteristics of Coronavirus Disease 2019 in China. *N Engl J Med.* 2020; 382(18): 1708-1720.
4. Al Hijaj, B. A. A., Al-Rubaye, A. K., Al-Hashim, Z. T., Mohammed, M. A., Habib, O. S. A Study on 696 COVID-19 Cases in Basrah-Southern Iraq: Severity and Outcome Indicators. *Iraqi Natl J Med.* 2020; 2(3): 16-26.
5. Wang, W., Xu, Y., Gao, R., Lu, R., Han, K., Wu, G., *et al.*, Detection of SARS-CoV-2 in Different Types of Clinical Specimens. *JAMA.* 2020; 323(18):1843-1844.
6. Fang, Y., Zhang, H., Xie, J., Lin, M., Ying, L., Pang, P., Ji, W., *et al.*, Sensitivity of Chest CT for COVID-19: Comparison to RT-PCR. *Radiology.* 2020; 296(2): E115-E117.
7. Kanne, J. P. Chest CT Findings in 2019 Novel Coronavirus (2019-nCoV) Infections from Wuhan, China: Key Points for the Radiologist. *Radiology.* 2020; 295(1): 16-17.
8. Bernheim, A., Mei, X., Huang, M., Yang, Y., Fayad, Z. A., Zhang, N., *et al.*, Chest CT findings in coronavirus disease-19 (COVID-19): relationship to duration of infection. *Radiology.* 2020; 295(3): 200463.
9. Xie, X., Zhong, Z., Zhao, W., Zheng, C., Wang, F., Liu, J. Chest CT for typical coronavirus disease 2019 (COVID-19) pneumonia: relationship to negative rt-pcr testing. *Radiology.* 2020; 296(2): E41-E45.
10. Wang, L., Lin, Z. Q., Wong, A. COVID-Net: a tailored deep convolutional neural network design for detection of COVID-19 cases from chest X-ray images. *Sci Rep.* 2020; 10(1): 19549.
11. Ai, T., Yang, Z., Hou, H., Zhan, C., Chen, C., Lv, W., *et al.*, Correlation of chest CT and RT-PCR testing for coronavirus disease 2019 (COVID-19) in China: A Report of 1014 Cases. *Radiology.* 2020; 296(2): E32-E40.
12. Yuan, M., Yin, W., Tao, Z., Tan, W., Hu, Y. Association of radiologic findings with mortality of patients infected with 2019 novel coronavirus in Wuhan, China. *PLoS One.* 2020; 15(3): e0230548.
13. Salehi, S., Abedi, A., Balakrishnan, S., Gholamrezanezhad, A. Coronavirus disease 2019 (COVID-19): A systematic review of imaging findings in 919 patients. *AJR Am J Roentgenol.* 2020; 215: 87-93.
14. Li, K., Fang, Y., Li, W., Pan, C., Qin, P., Zhong, Y., *et al.*, CT image visual quantitative evaluation and clinical classification of coronavirus disease (COVID-19). *Eur Radiol.* 2020; 30(8): 4407-4416.
15. Huang, L., Han, R., Ai, T., Yu, P., Kang, H., Tao, Q., *et al.*, Serial quantitative chest CT assessment of COVID-19: A deep learning approach. *Radiol Cardiothorac Imaging.* 2020; 2(2): e200075.
16. Lessmann, N., Sánchez, C. I., Beenen, L., Boulogne, L. H., Brink, M., Calli, E., *et al.*, Automated Assessment of COVID-19 reporting and data system and chest CT severity scores in patients suspected of having COVID-19 using artificial intelligence. *Radiology.* 2021; 298(1): E18-E28.
17. Dangis, A., De Brucker, N., Heremans, A., Gillis, M., Frans, J., Demeyere, A., *et al.*, Impact of gender on extent of lung injury in COVID-19. *Clin Radiol.* 2020; 75(7): 554-556.
18. Guan, W. J., Liang, W. H., Zhao, Y., Liang, H. R., Chen, Z. S., Li, Y. M., *et al.*, Comorbidity and its impact on 1590 patients with COVID-19 in China: a nationwide

- analysis. European Respiratory Journal. 2020; 55(5): 2000547.
19. Parry, A. H., Wani, A. H., Yaseen, M., Dar, K. A., Choh, N. A., Khan, N. A., *et al.*, Spectrum of chest computed tomographic (CT) findings in coronavirus disease-19 (COVID-19) patients in India. Eur J Radiol. 2020; 129: 109147.
 20. Omar, S., Motawea, A. M., Yasin, R. High-resolution CT features of COVID-19 pneumonia in confirmed cases. Egyptian Journal of Radiology and Nuclear Medicine. 2020; 51: 121.
 21. Sultan, O. M., Al-Tameemi, H., Alghazali, D. M., Abed, M., Ghniem, M. N. A., Hawiji, D. A., *et al.*, Pulmonary CT manifestations of COVID-19: changes within 2 weeks duration from presentation. Egypt J Radiol Nucl Med. 2020; 51(1): 105.